

Causas inusuales de ACV

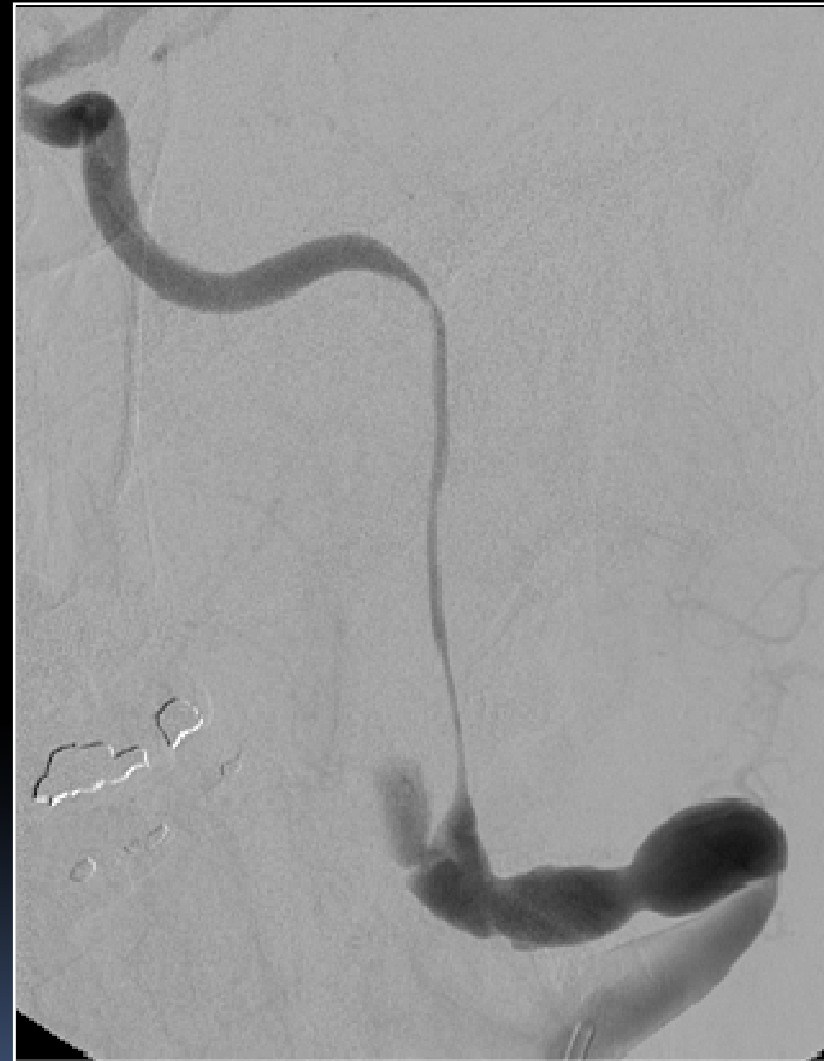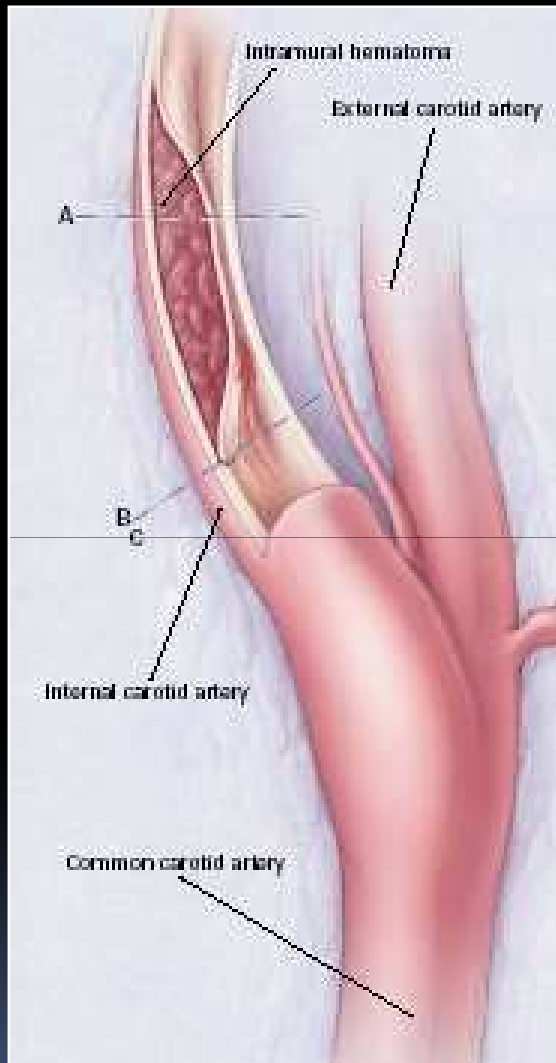
Javier Moschini

Médico Neurólogo

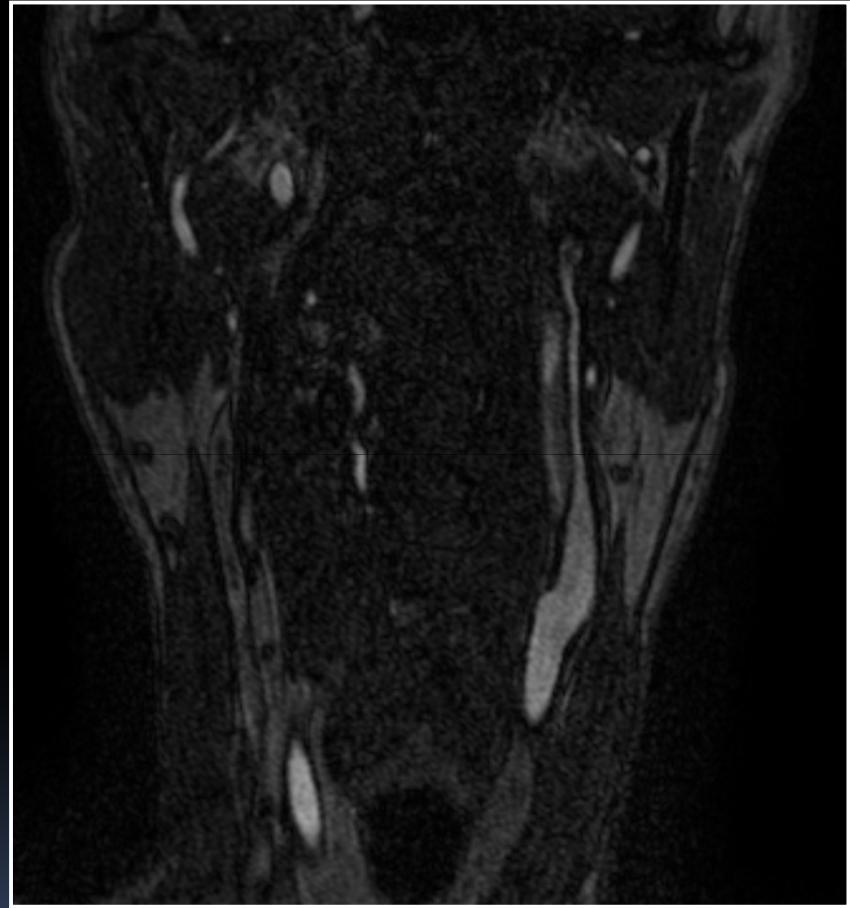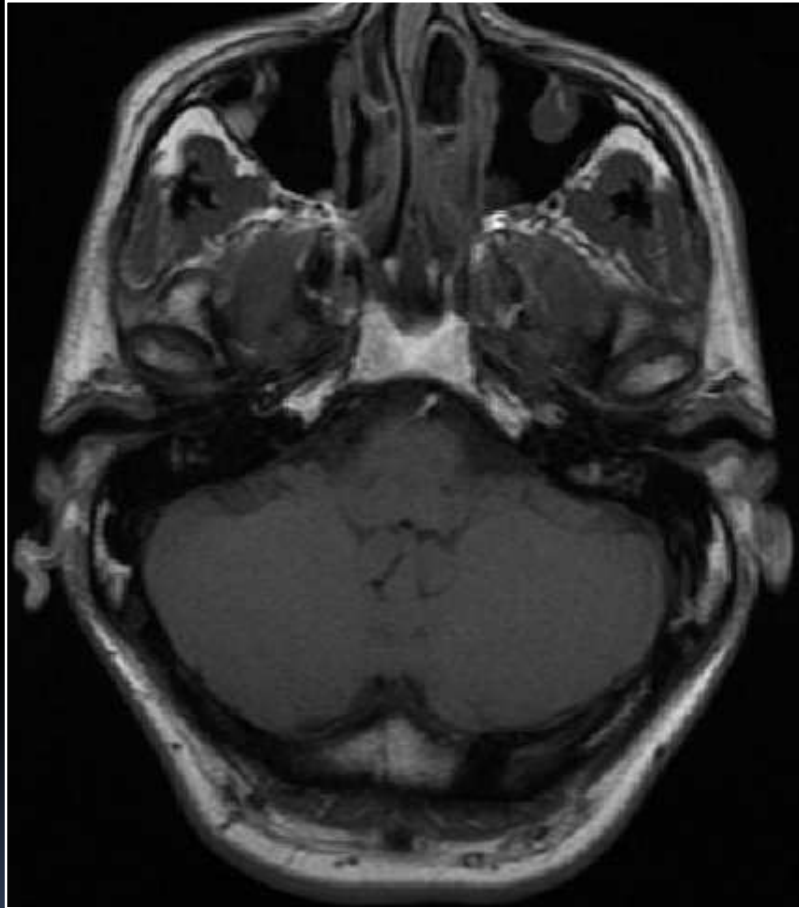
Centro de ACV, Instituto de Neurociencias

Hospital Universitario de la Fundación Favaloro

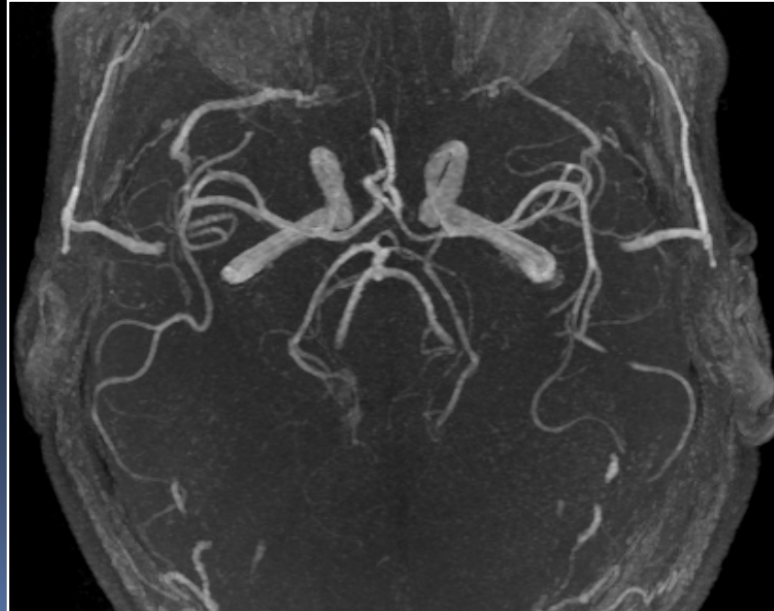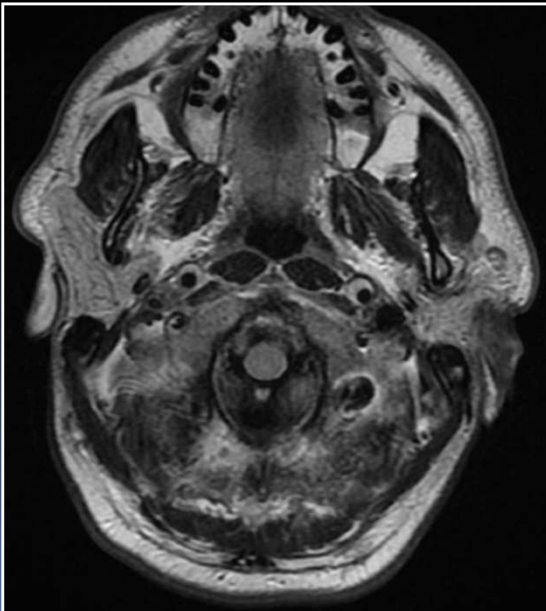
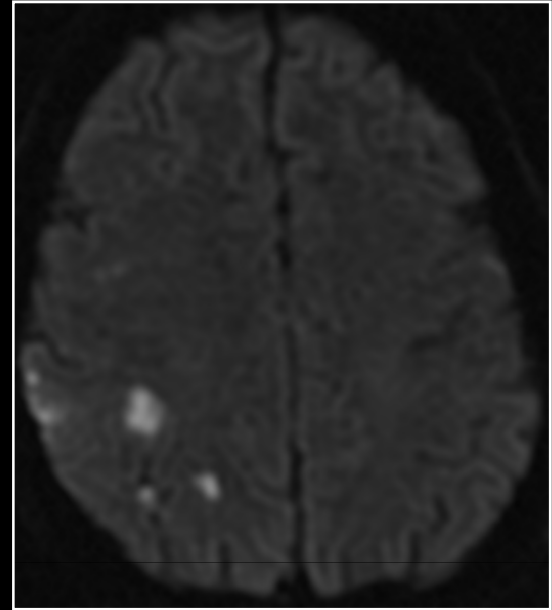
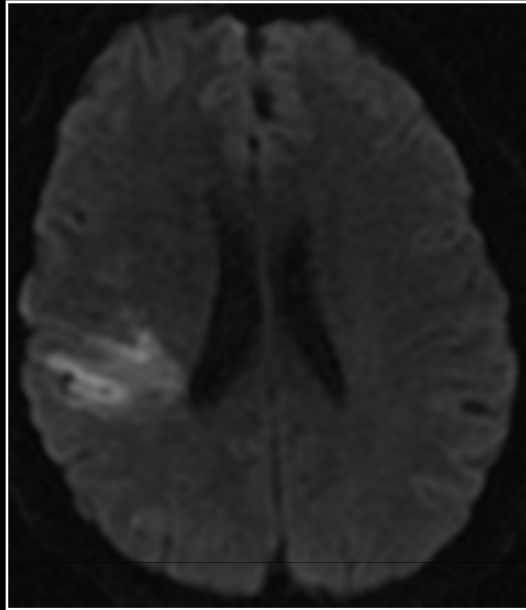
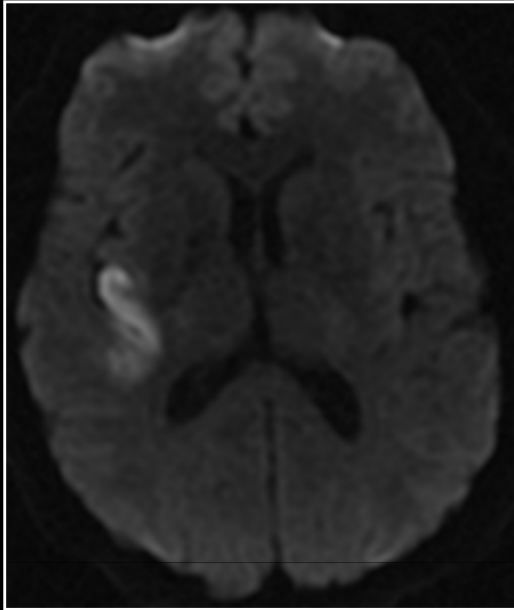
Disecciones arteriales cervicocefálicas



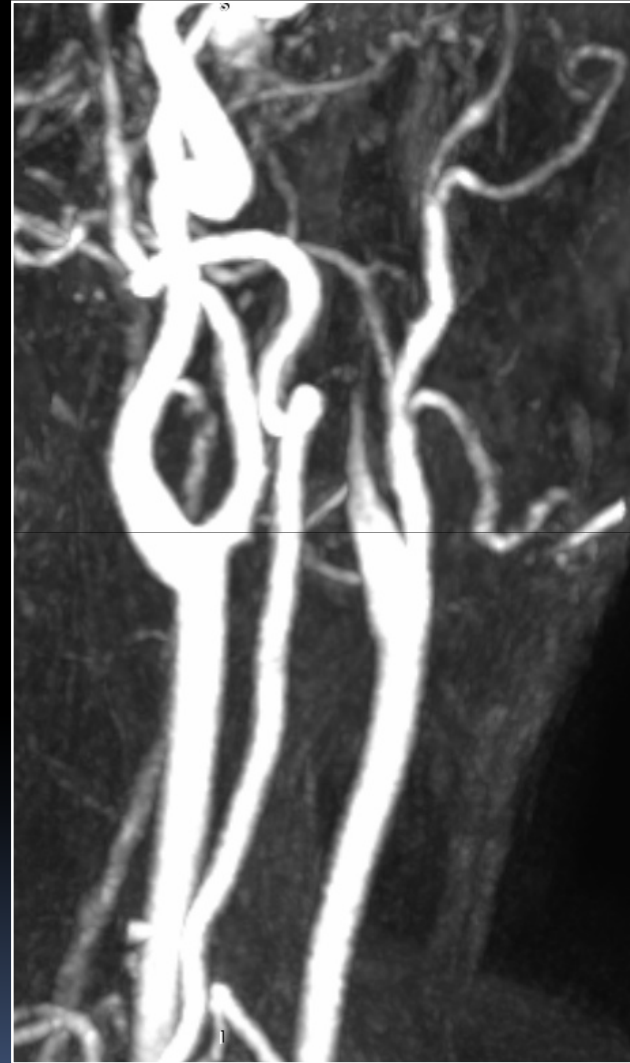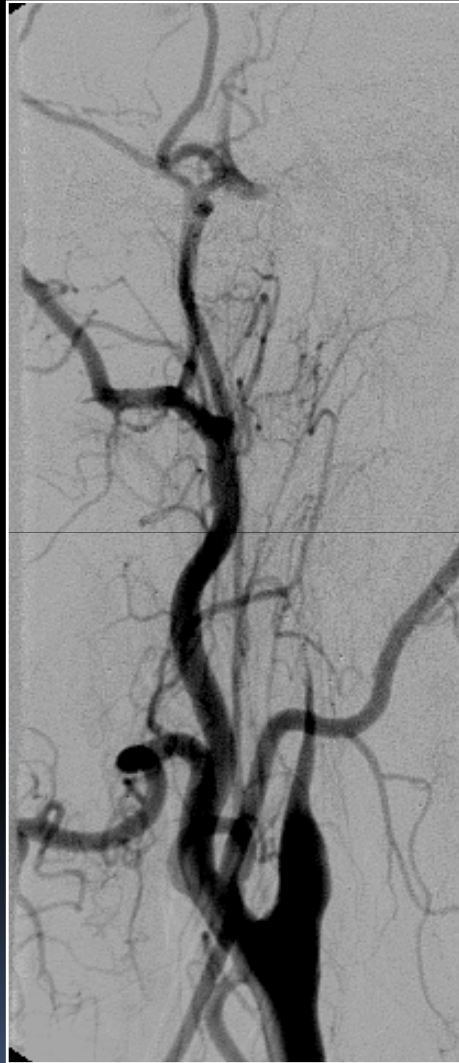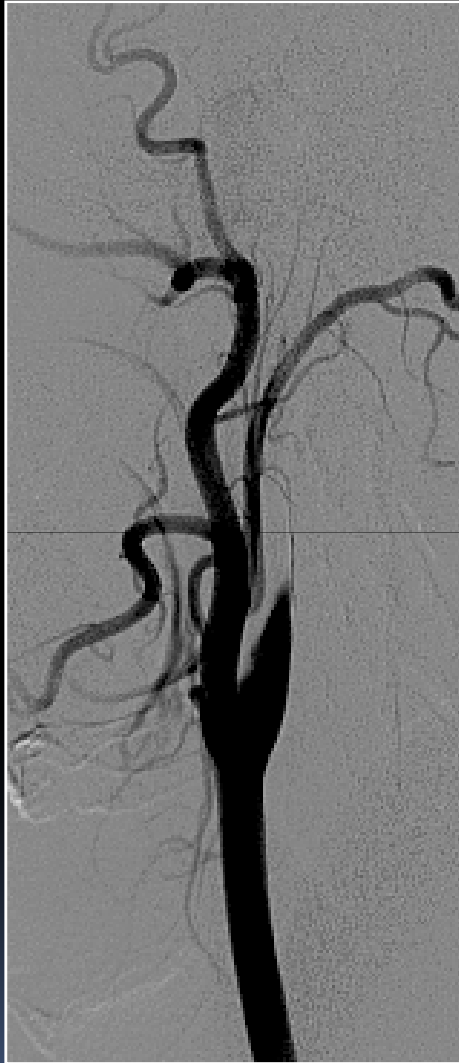Disecciones arteriales cervicocefálicas



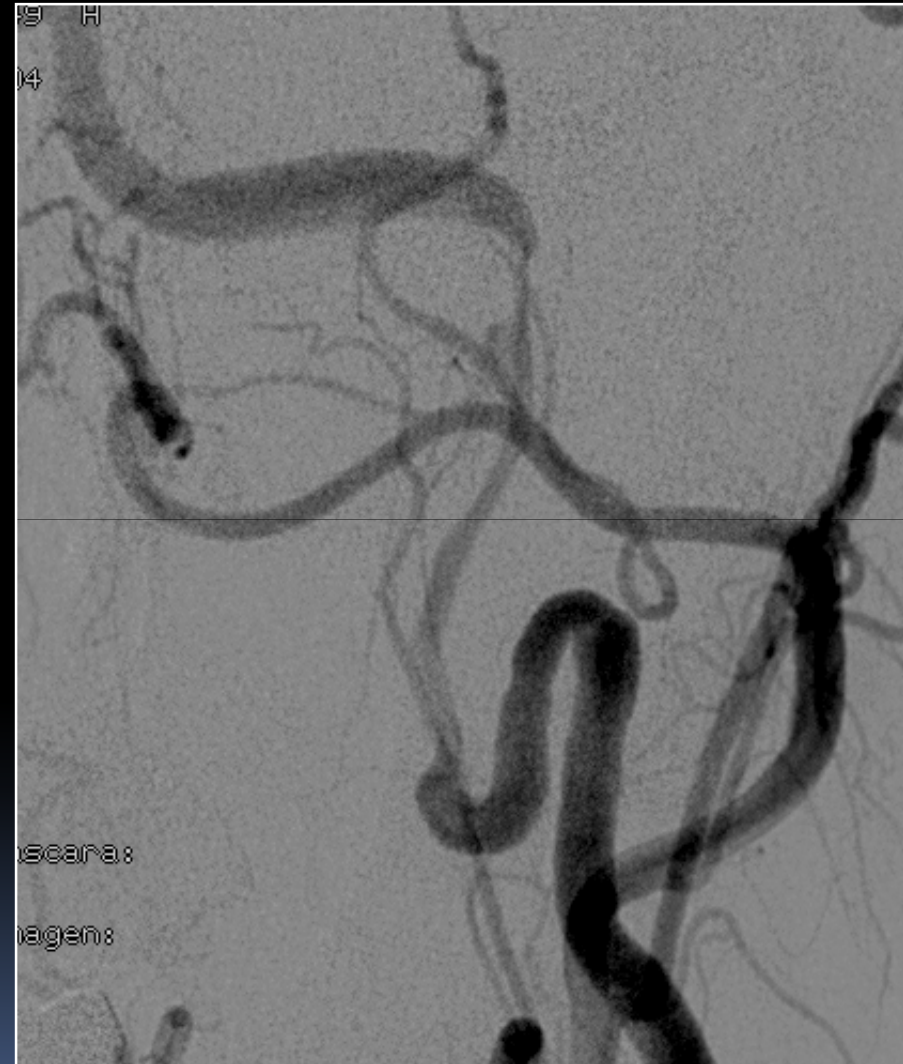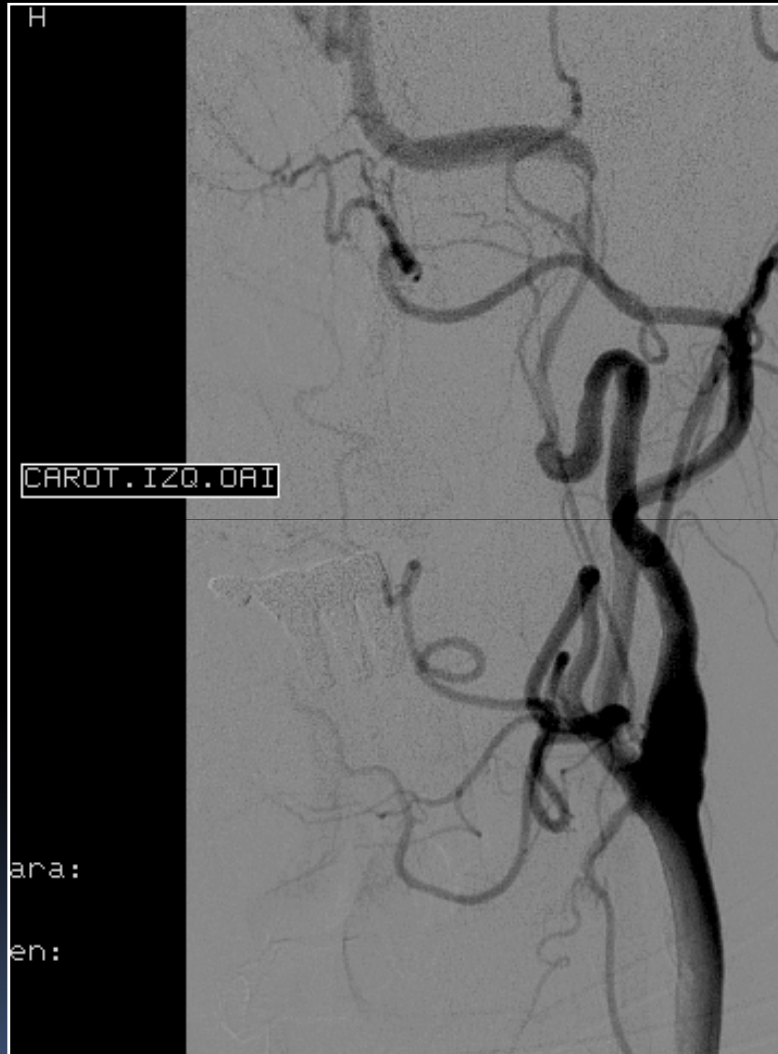Disecciones arteriales cervicocefálicas



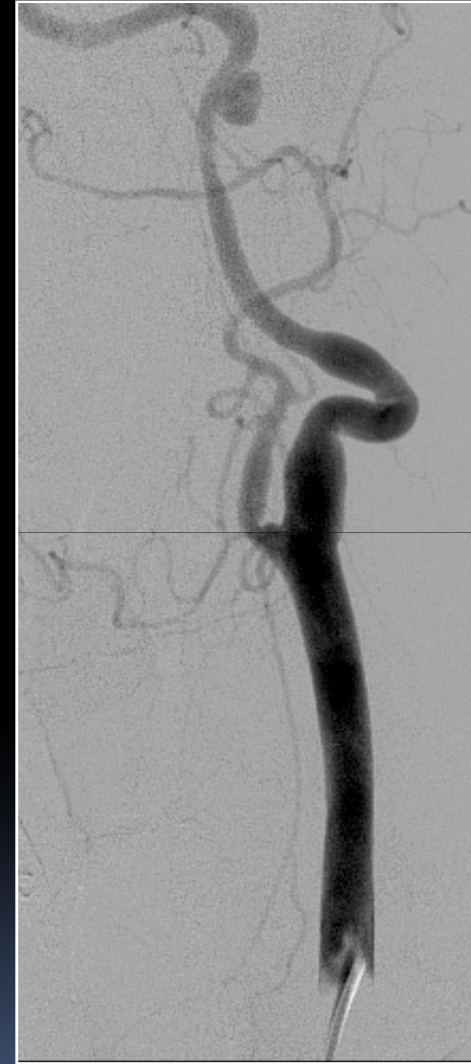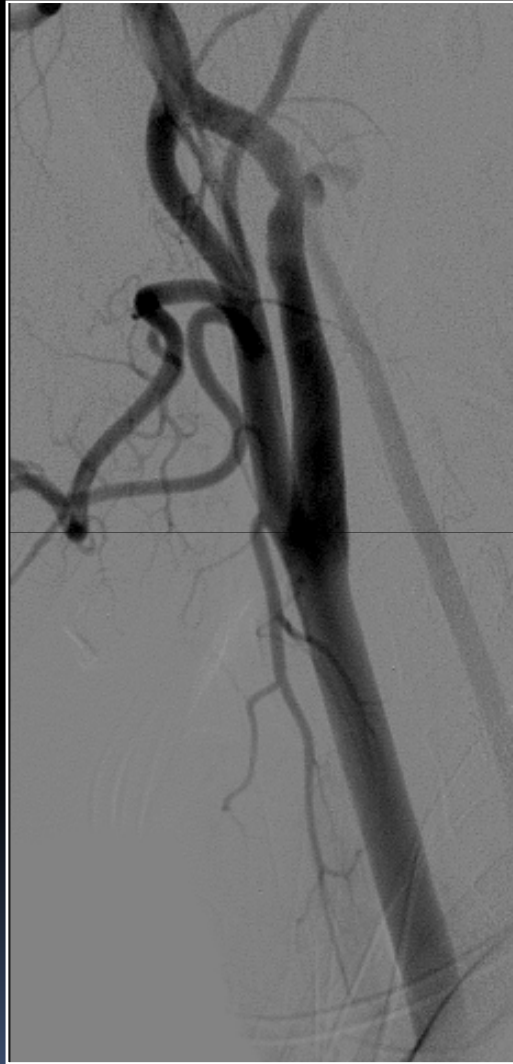
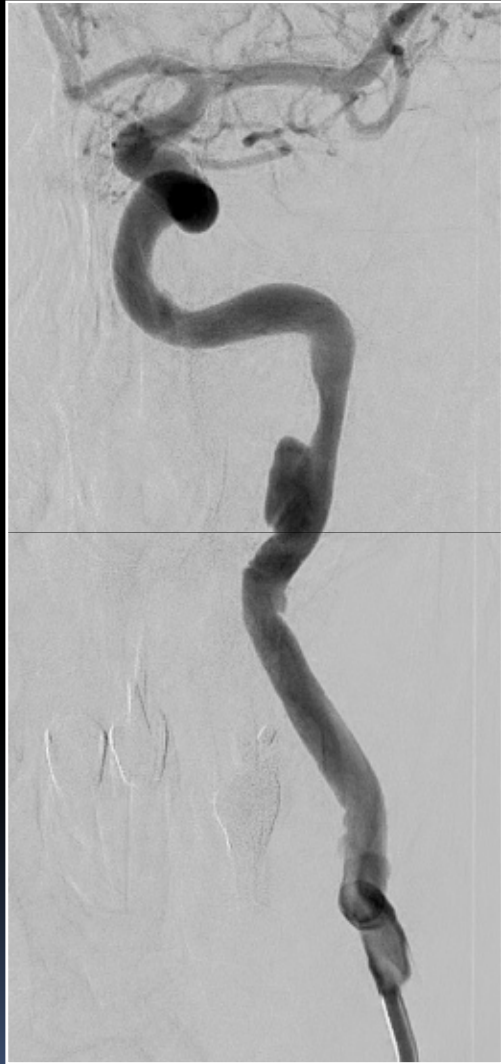Disecciones arteriales cervicocefálicas



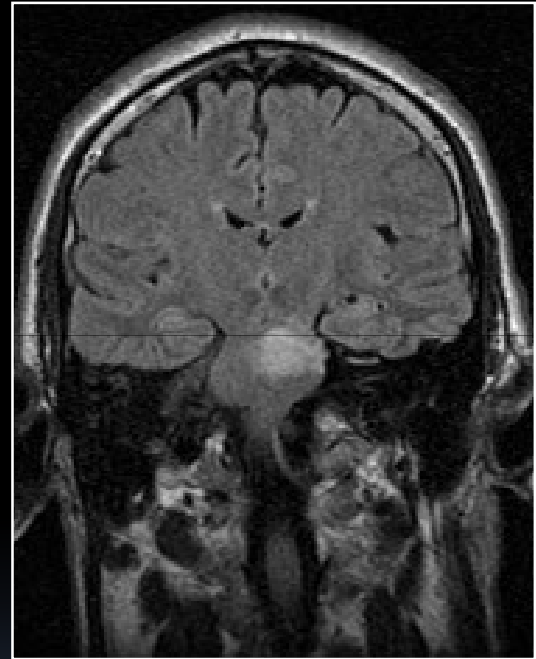
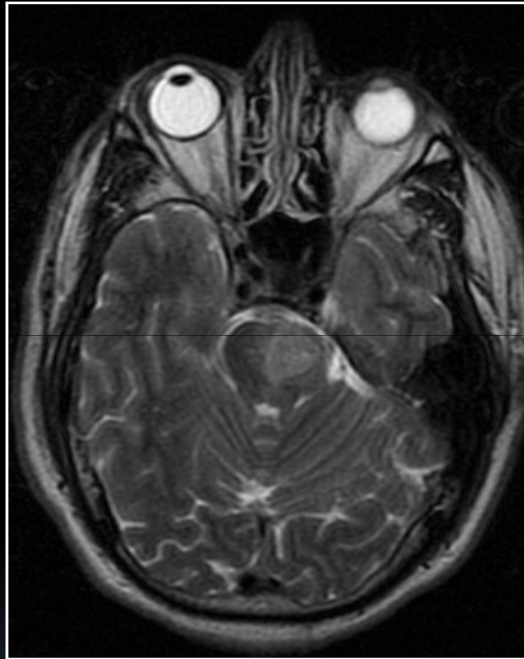
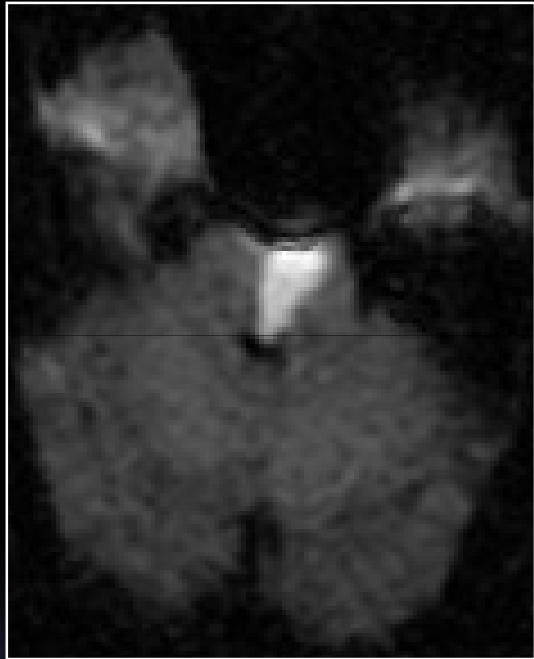
Disecciones arteriales cervicocefálicas



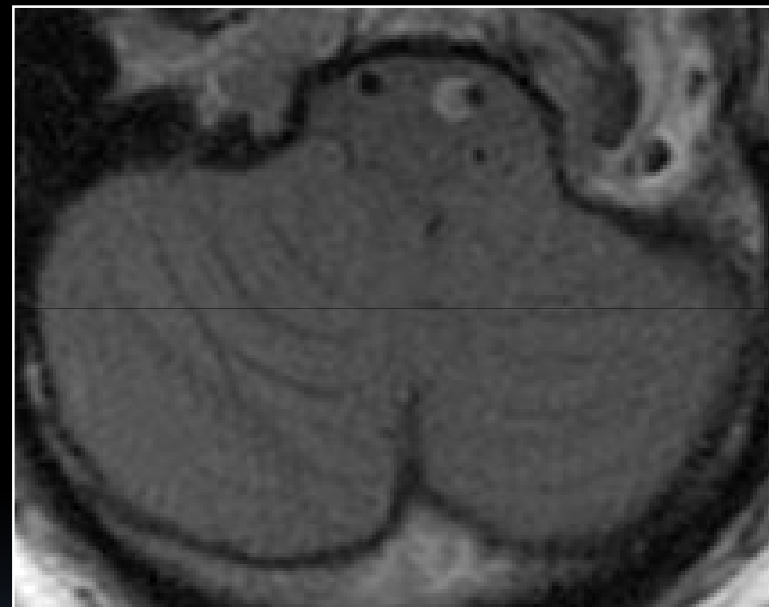
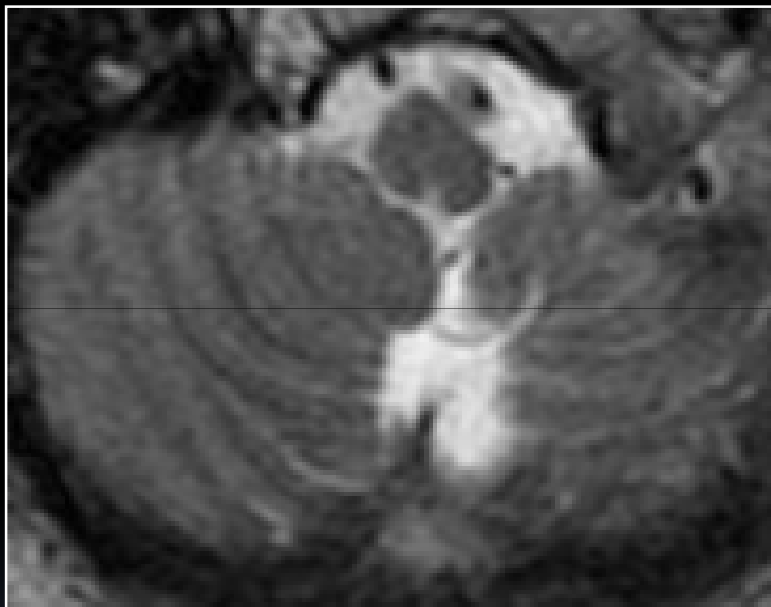
Disecciones arteriales cervicocefálicas



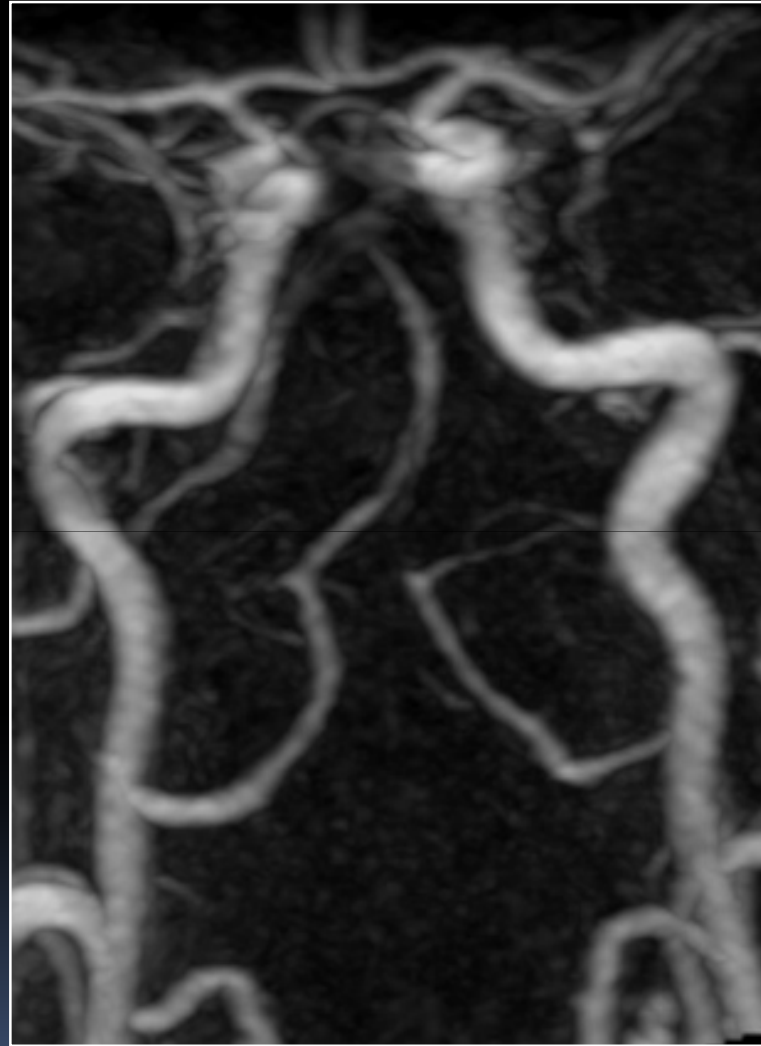
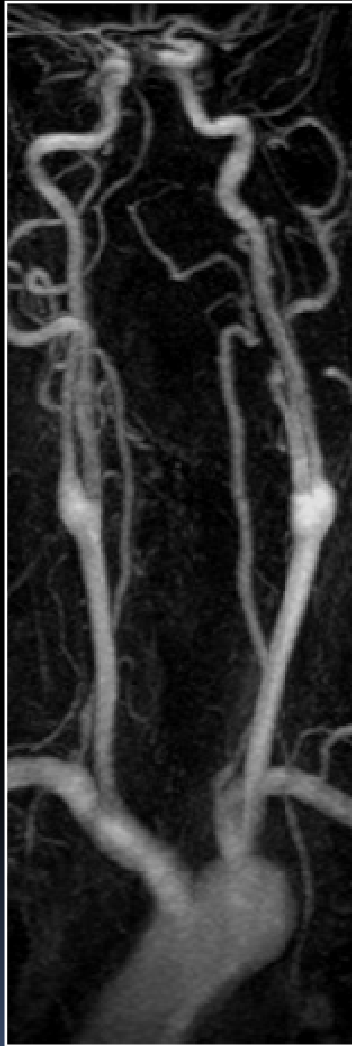
Disecciones arteriales cervicocefálicas



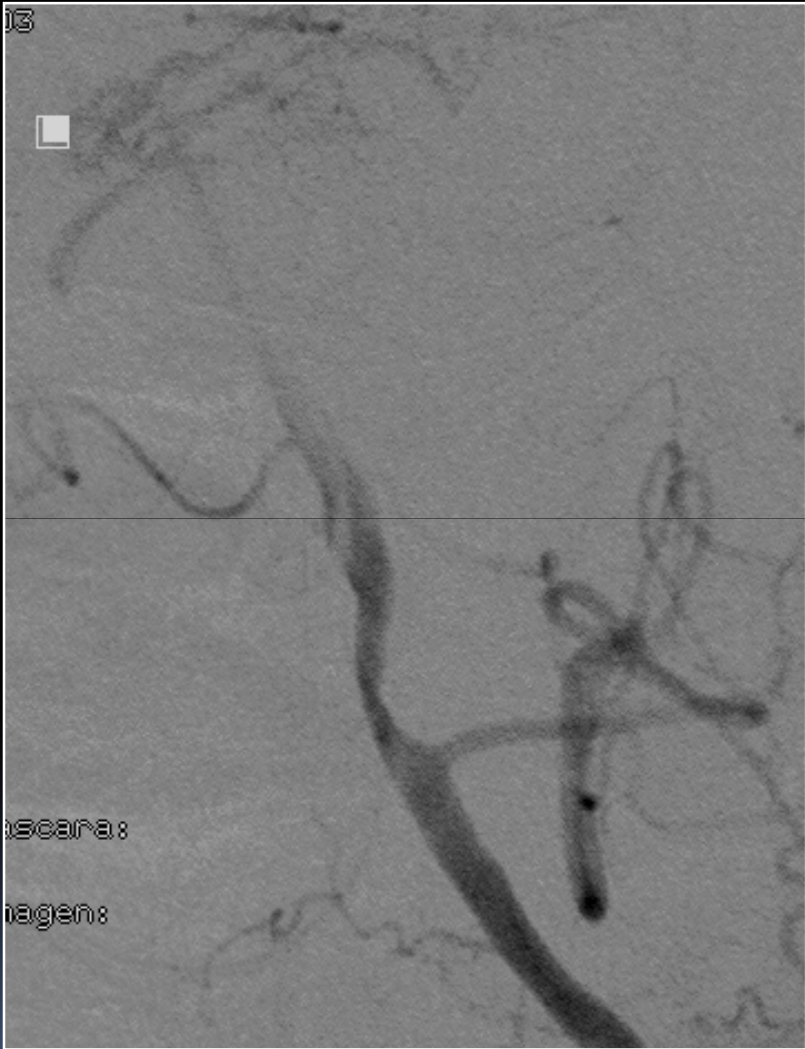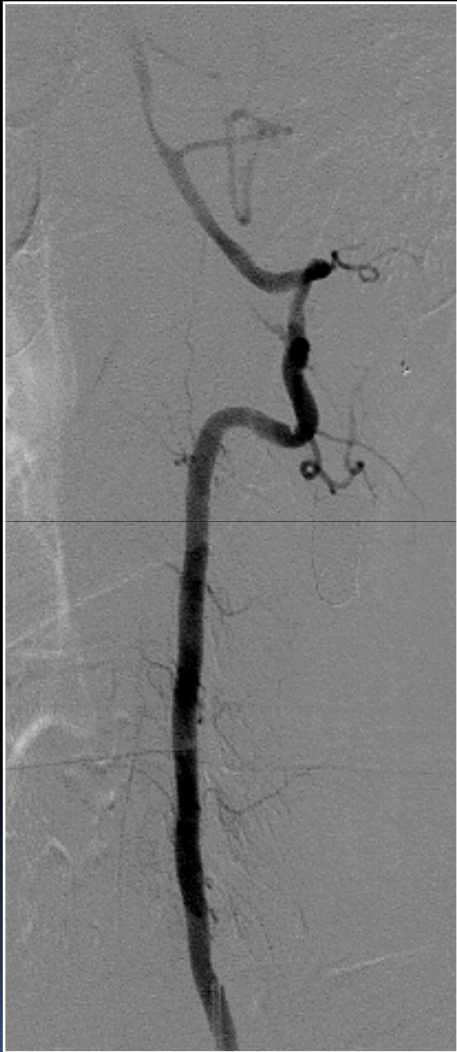Disecciones arteriales cervicocefálicas



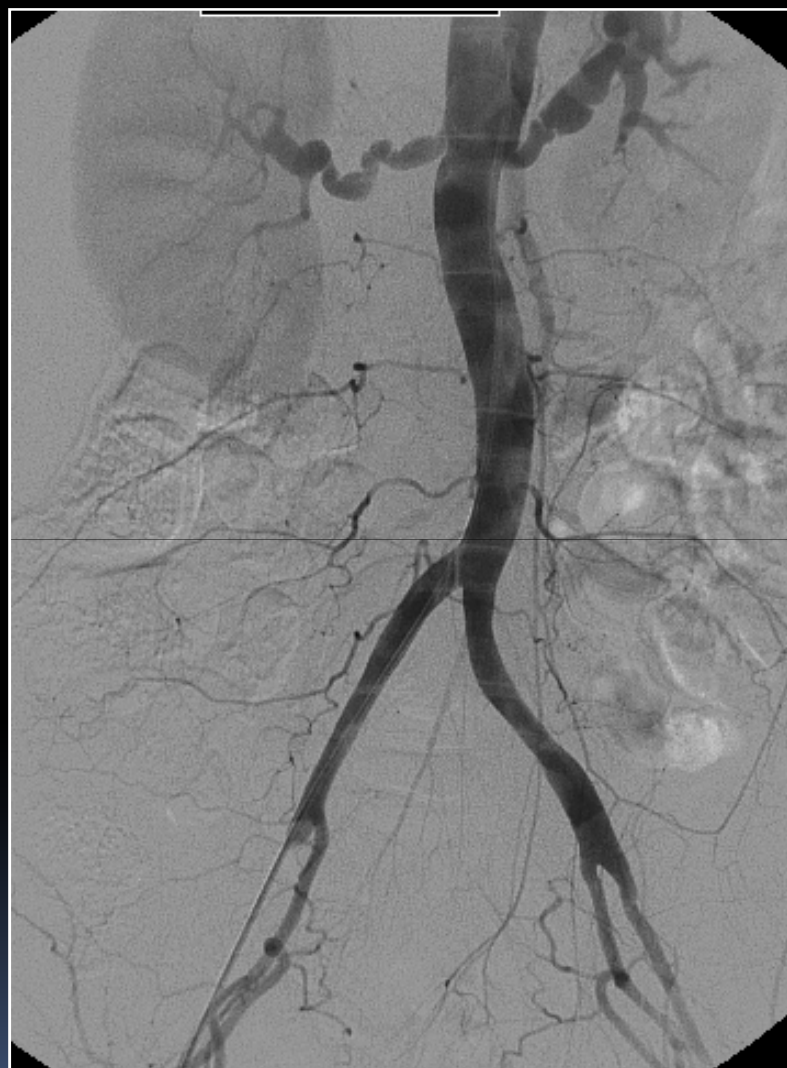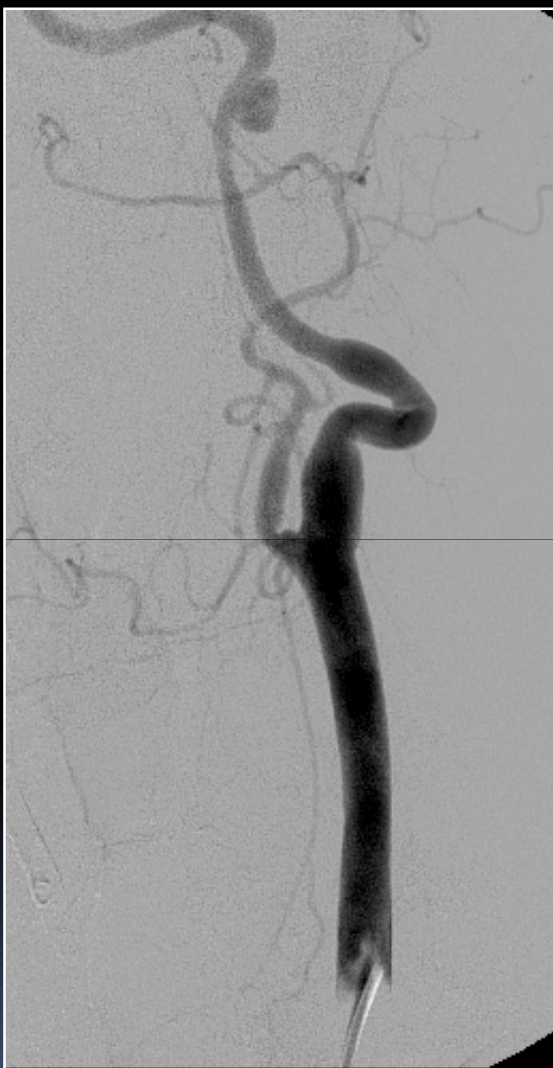Disecciones arteriales cervicocefálicas



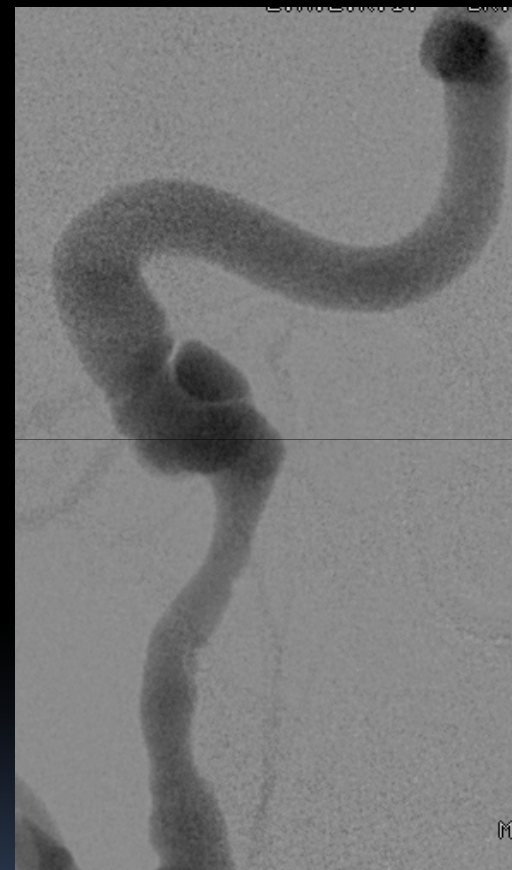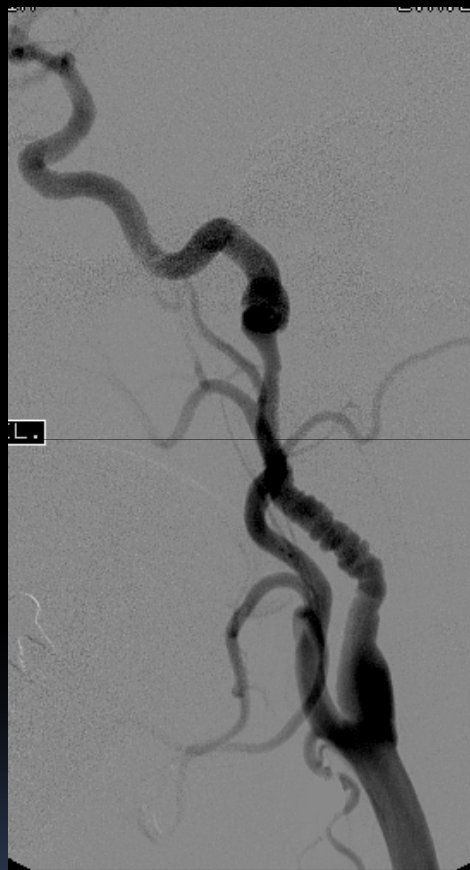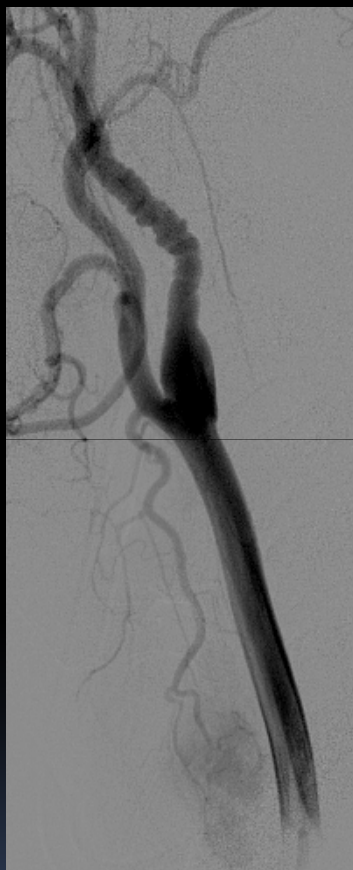Disecciones arteriales cervicocefálicas



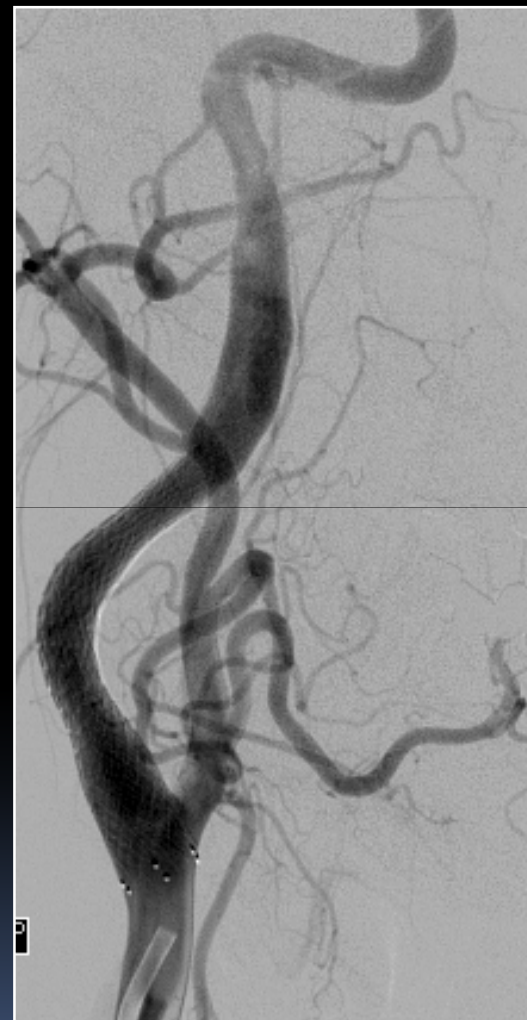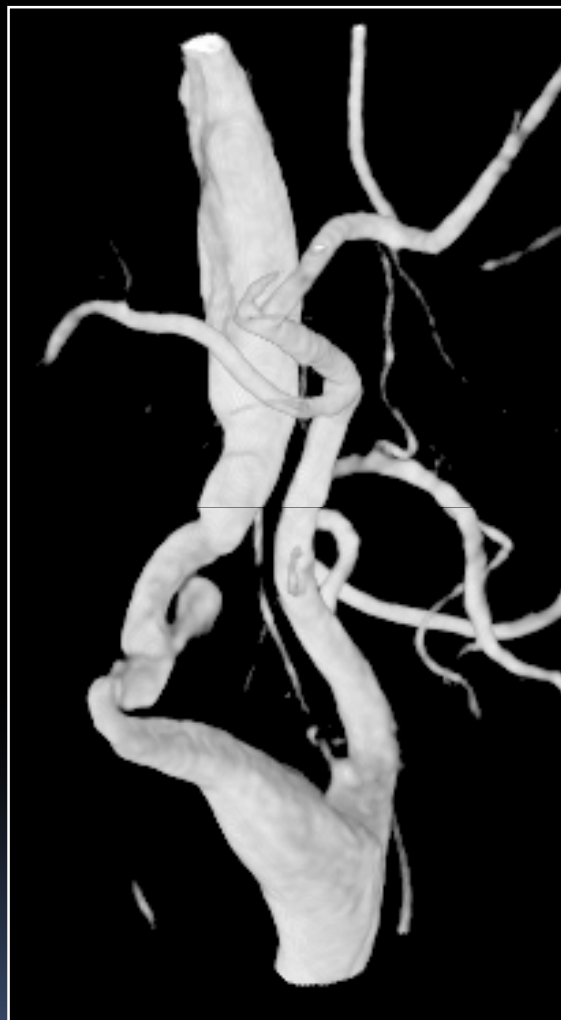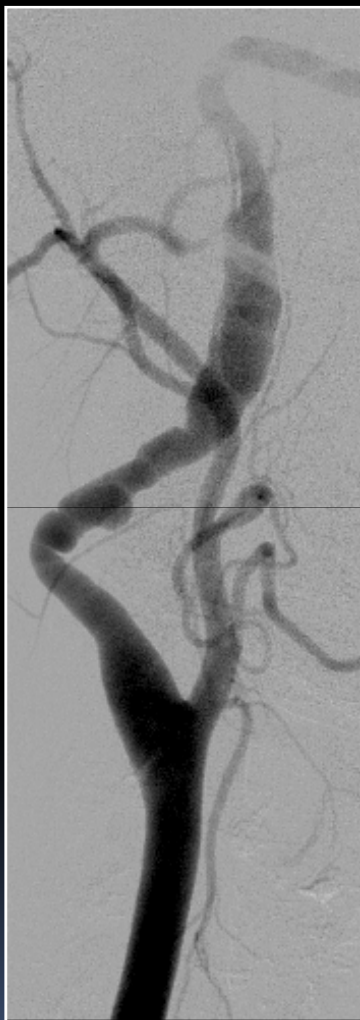Displasia fibromuscular



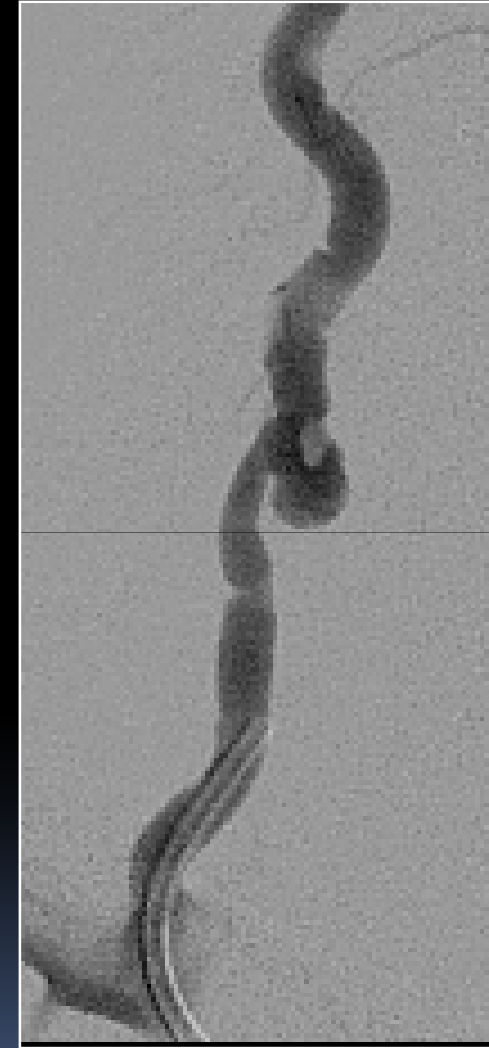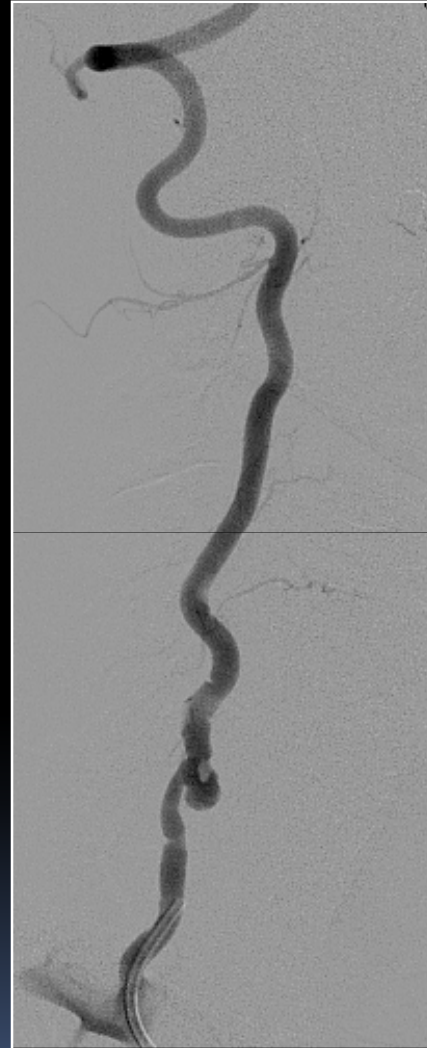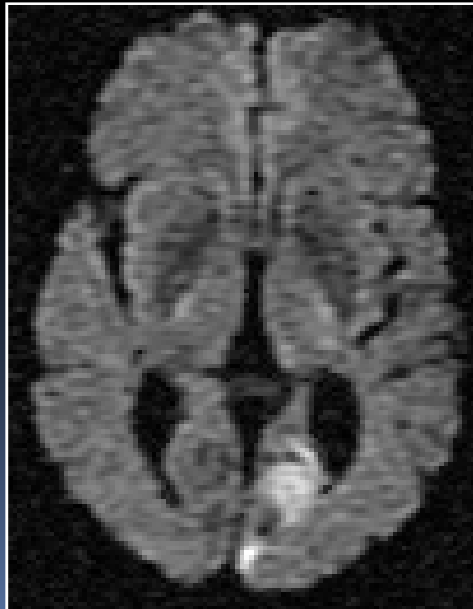
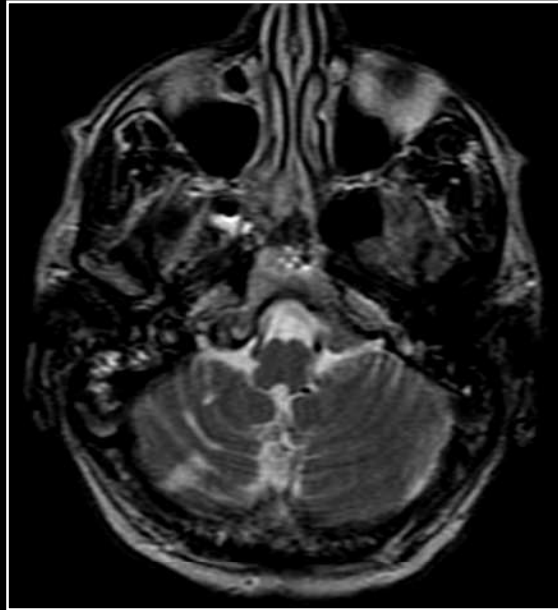
Displasia fibromuscular



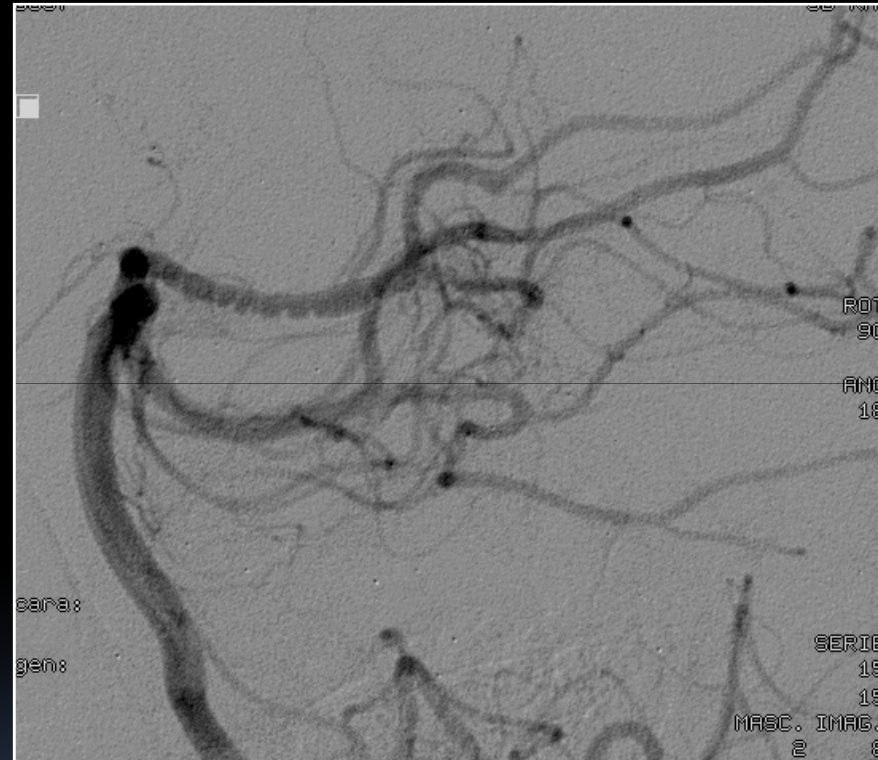
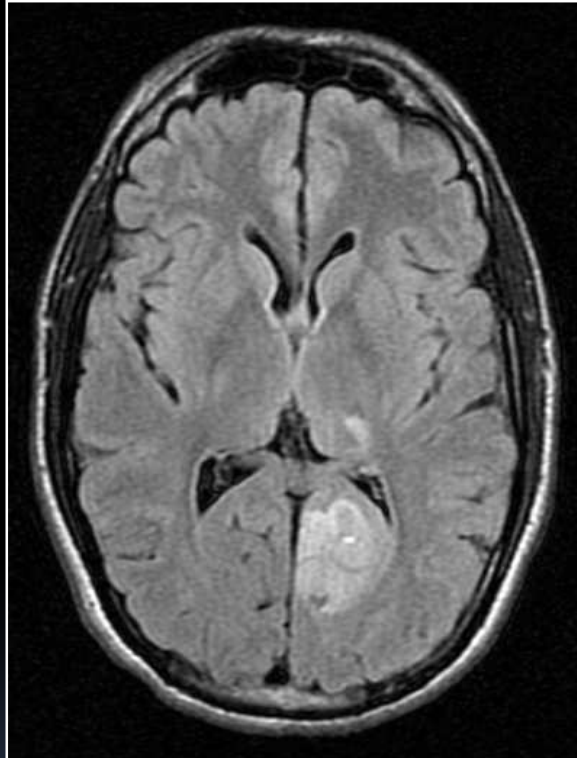
Displasia fibromuscular



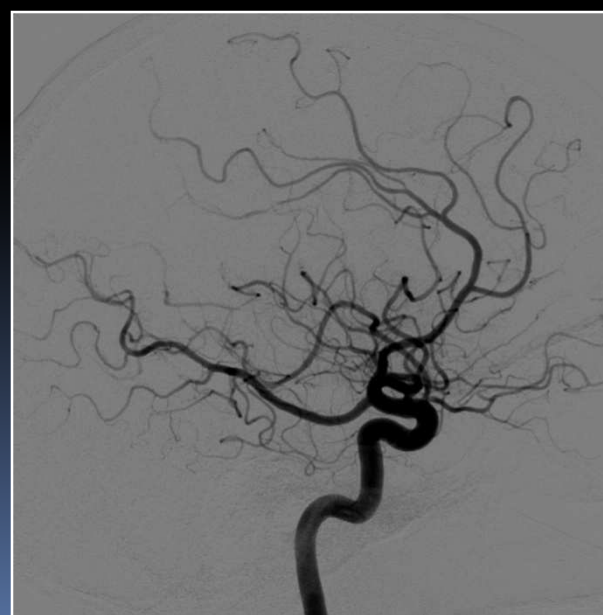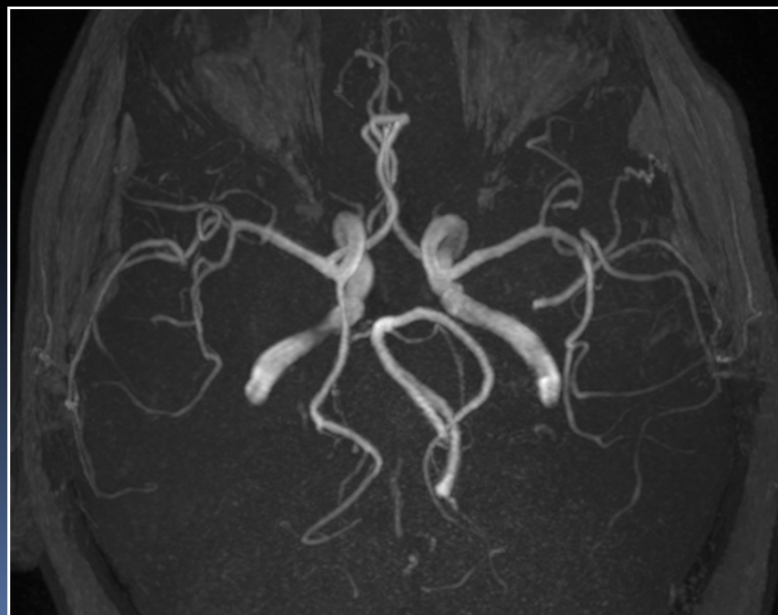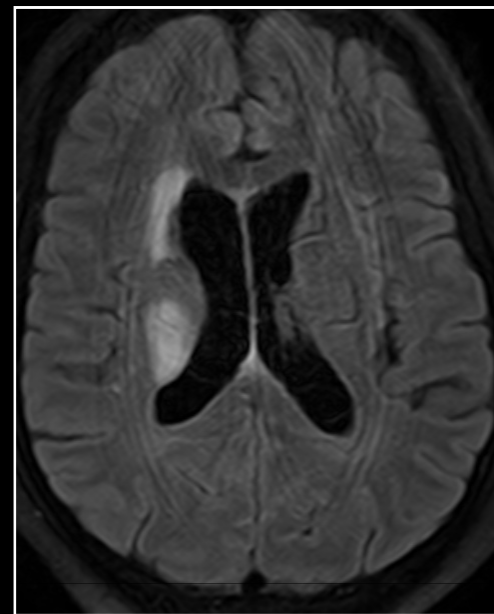
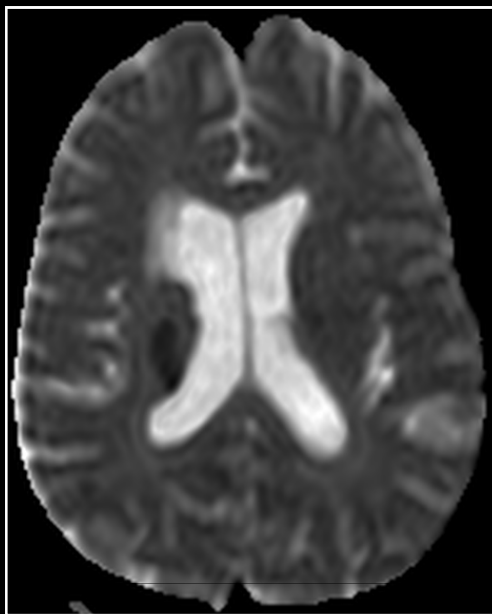
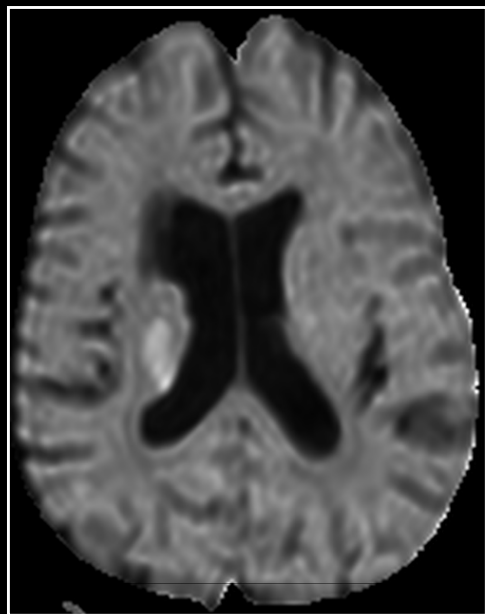
Displasia fibromuscular



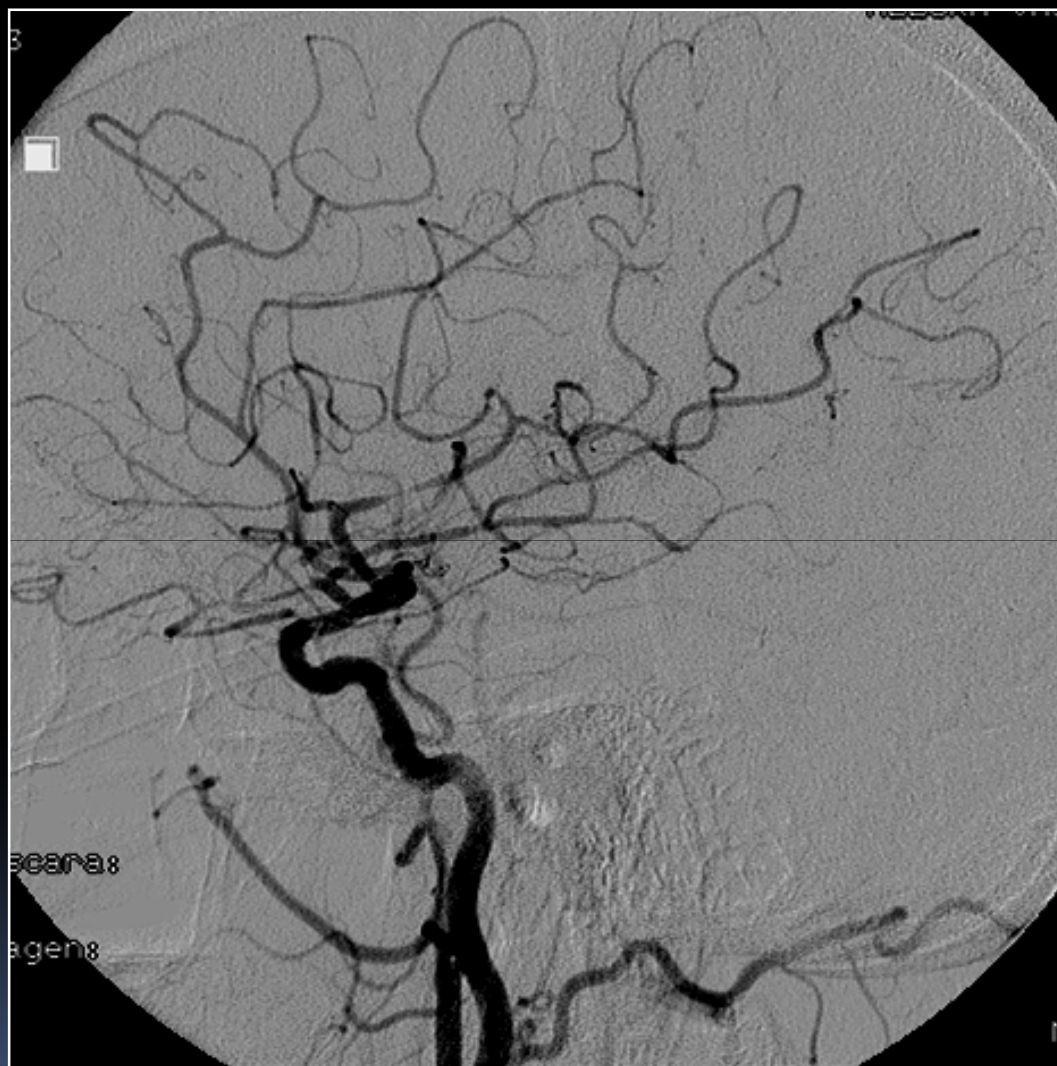
Displasia fibromuscular



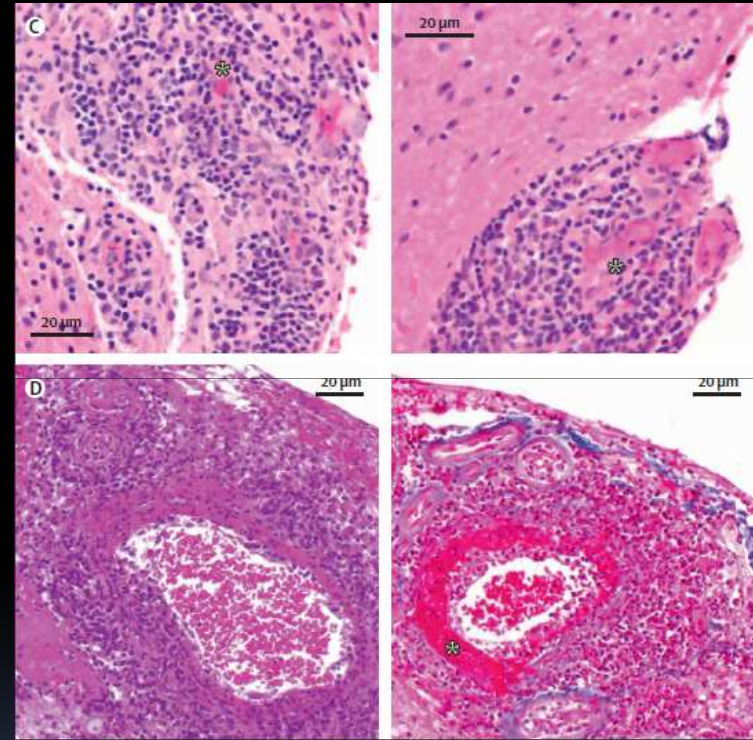
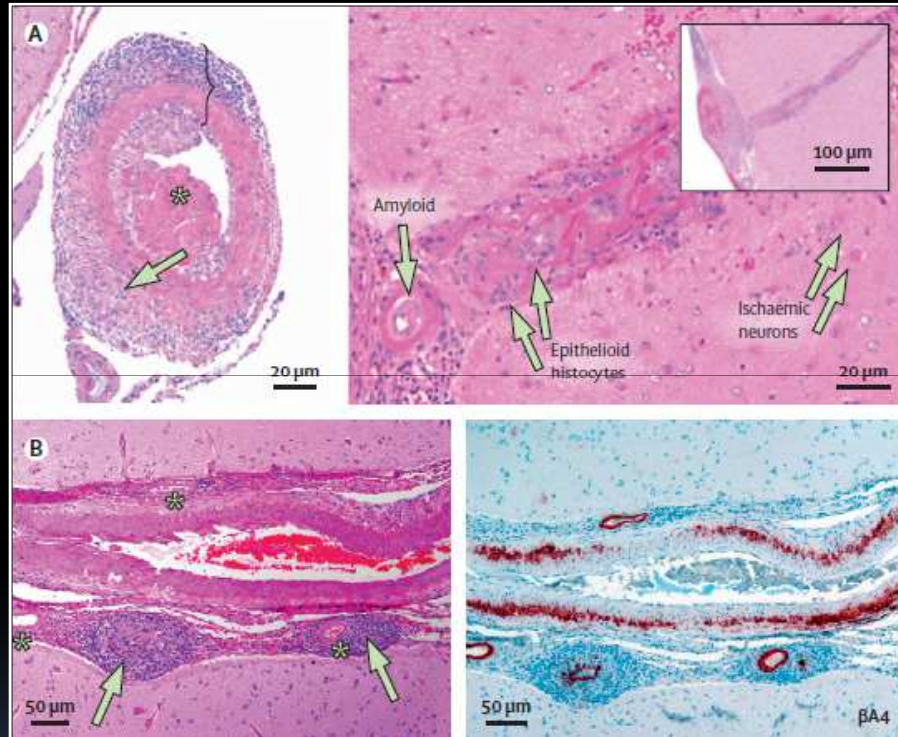
Vasculitis primaria de SNC



Vasculitis primaria de SNC



Vasculitis primaria de SNC



Panel: Causes of secondary CNS vasculitis

Viral infections

Varicella zoster virus, HIV, hepatitis C virus, cytomegalovirus, parvovirus B19

Bacterial infections

Treponema pallidum, *Borrelia burgdorferi*, *Mycobacterium tuberculosis*, *Mycoplasma pneumoniae*, *Bartonella henselae*, *Rickettsia* spp

Fungal infections

Aspergillosis, mucormycosis, coccidioidomycosis, candidosis

Parasitic infections

Cysticercosis

Systemic vasculitides

Wegener's granulomatosis, Churg-Strauss syndrome, Behçet's disease, polyarteritis nodosa, Henoch-Schönlein purpura, Kawasaki disease, giant-cell arteritis, Takayasu's arteritis

Connective tissue diseases

Systemic lupus erythematosus, rheumatoid arthritis, Sjögren's syndrome, dermatomyositis, mixed connective tissue disease

Miscellaneous

Antiphospholipid antibodies syndrome, Hodgkin's and non-Hodgkin lymphomas, neurosarcoidosis, inflammatory bowel disease, graft-versus-host disease, bacterial endocarditis, acute bacterial meningitis, drug-induced CNS vasculitis (cocaine, amphetamine, ephedrine, phenylpropanolamine)

Table 2. Differential Diagnosis of PACNS

Noninflammatory vasculopathies

RVCS

Atherosclerosis

Neurofibromatosis

Fibromuscular dysplasia

CADASIL

MELAS

Susac syndrome

Hypercoagulable state

Infections

Embolism from subacute bacterial endocarditis

Basilar meningitis caused by TB or fungal infection

Bacterial infections

Parainfection syndromes (eg, ADEM)

Demyelinating syndromes

Multiple sclerosis

ADEM

Sarcoidosis

CNS vasculitis, secondarily affected as part of a primary vasculitis

Large-vessel vasculitis (eg, giant-cell arteritis, Takayasu arteritis)

Medium-vessel vasculitis (eg, polyarteritis nodosa, Kawasaki disease)

Small-vessel vasculitis

ANCA-associated vasculitis (eg, Wegener granulomatosis, Churg-Strauss syndrome, microscopic polyangiitis)

Immune-complex deposition (eg, Henoch-Schönlein purpura, cryoglobulinemia)

Rheumatic syndromes (eg, lupus, Sjögren syndrome, scleroderma)

Malignant diseases

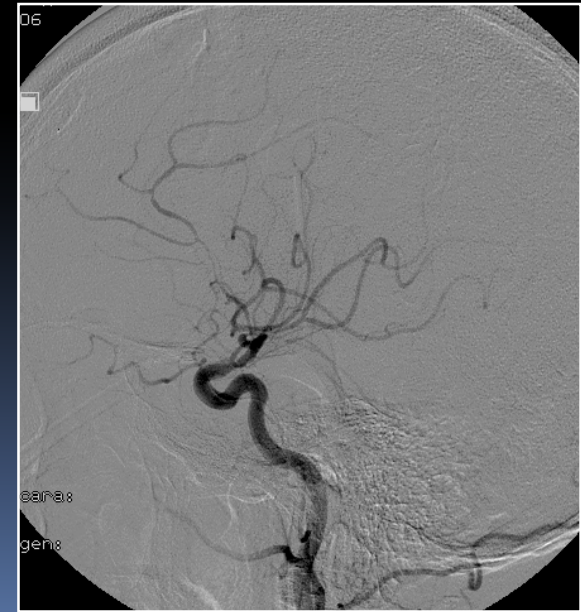
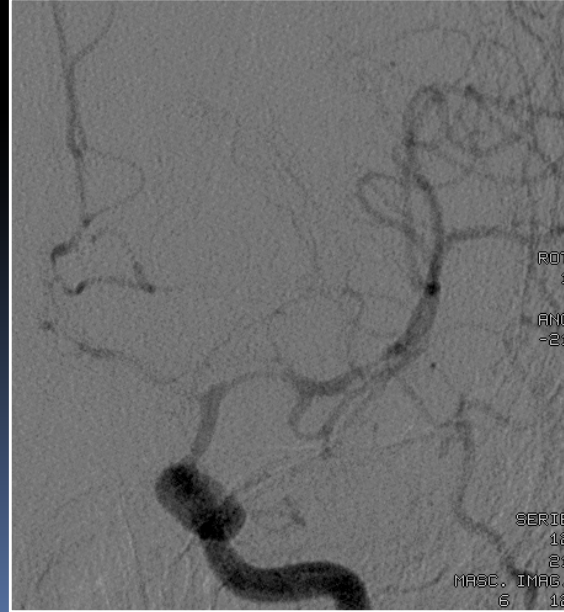
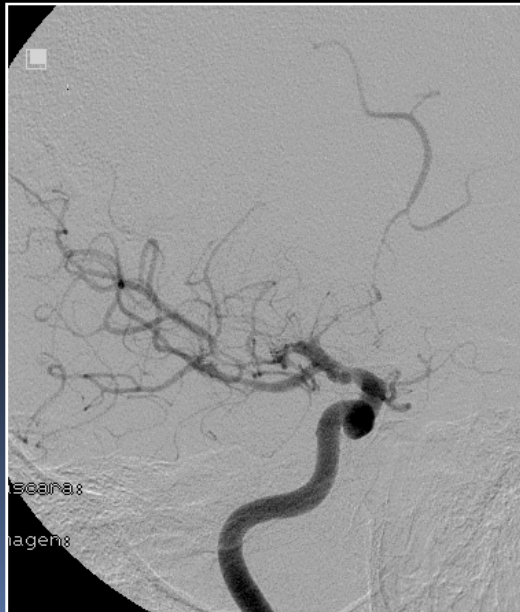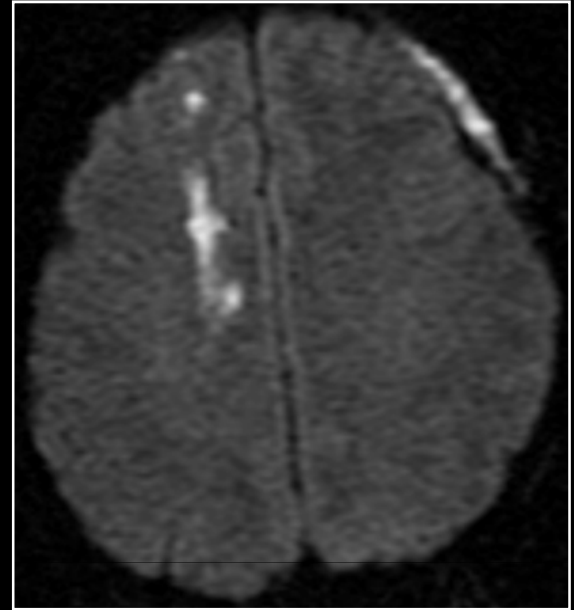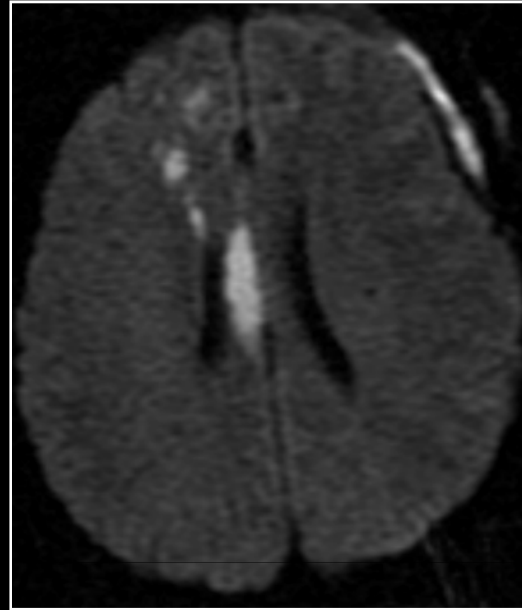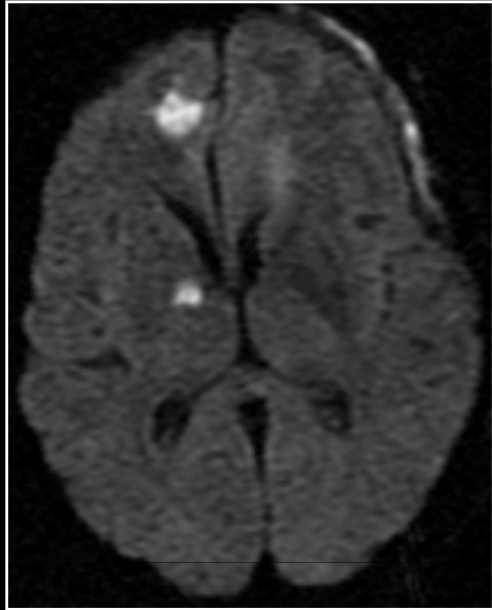
Primary CNS lymphoma

Lymphomatoid granulomatosis

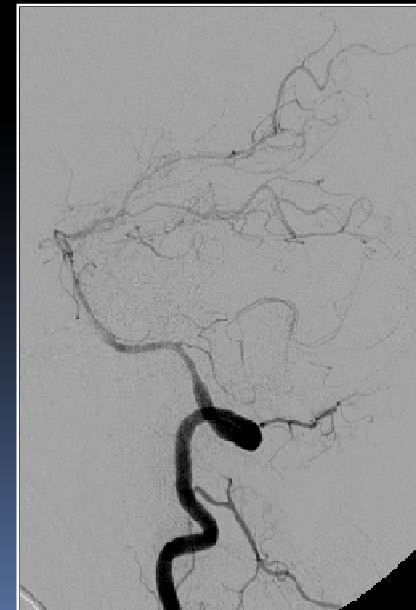
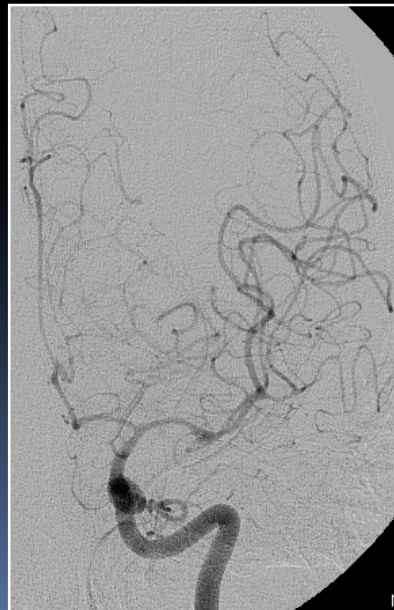
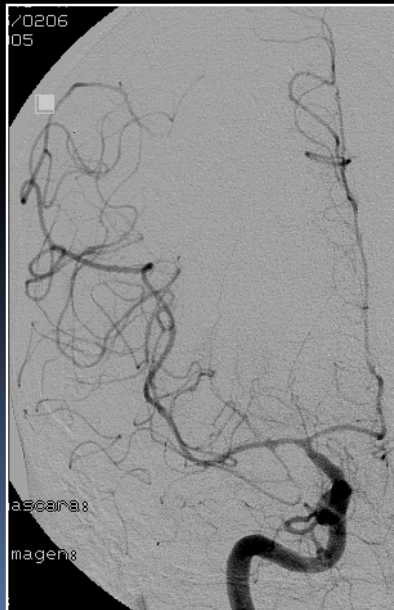
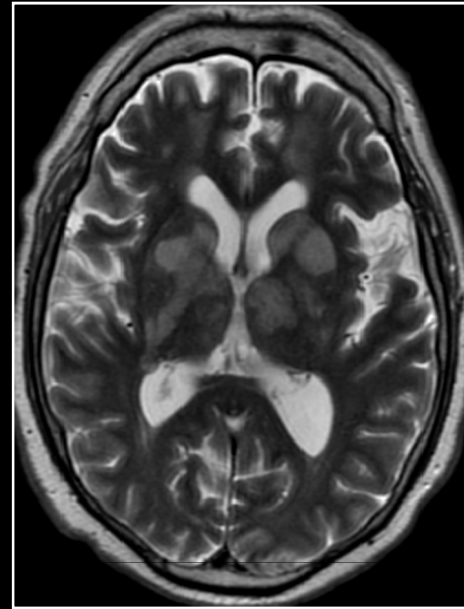
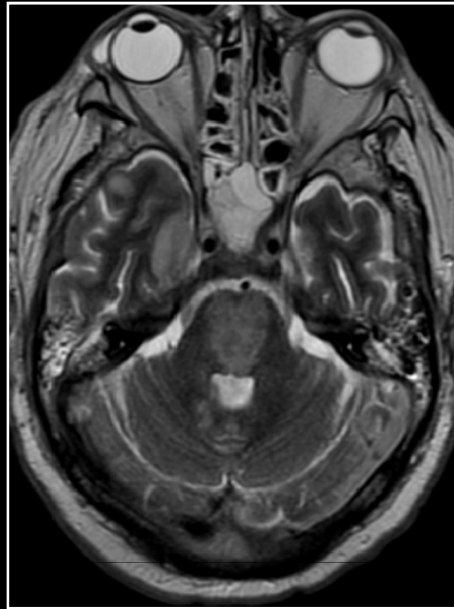
Carcinomatous meningitis

Gliomatosis cerebri

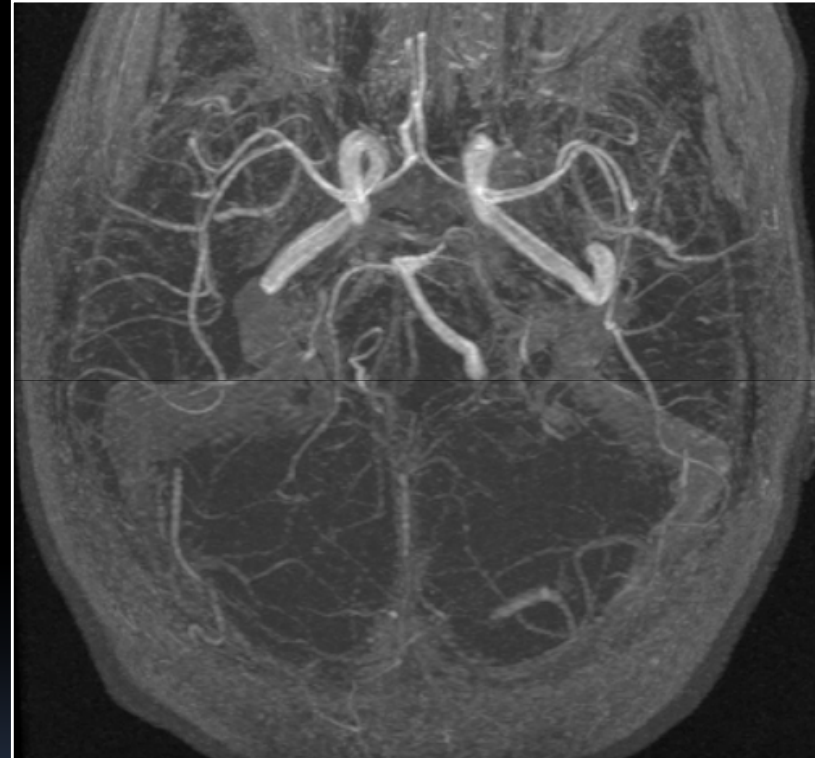
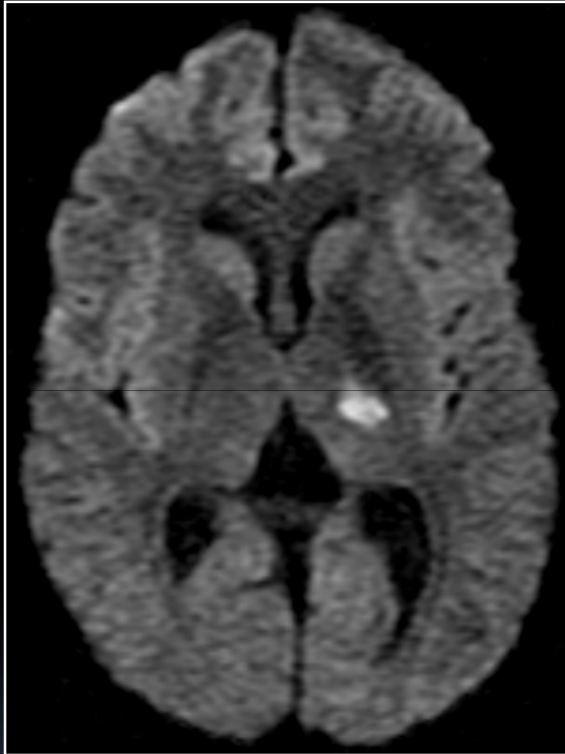Vasculitis infecciosa (staphylococcus aureus)



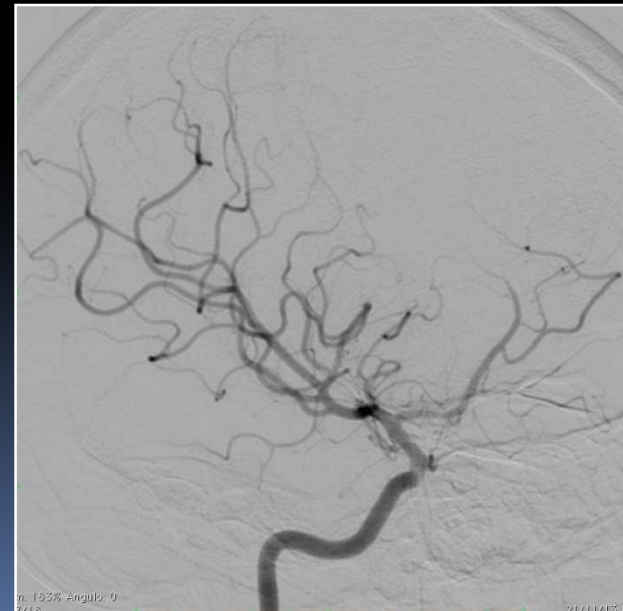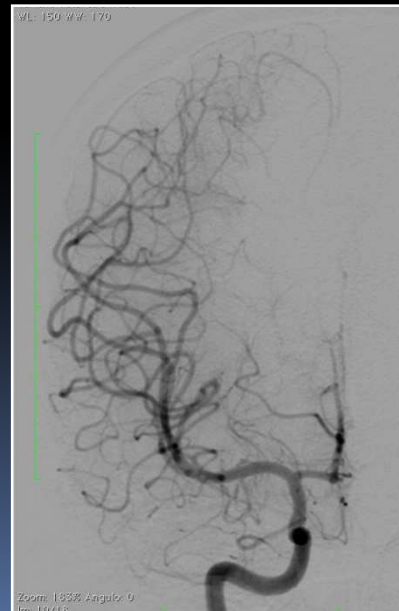
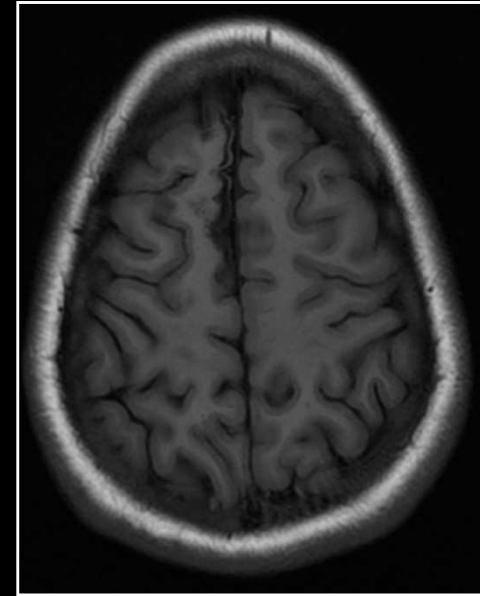
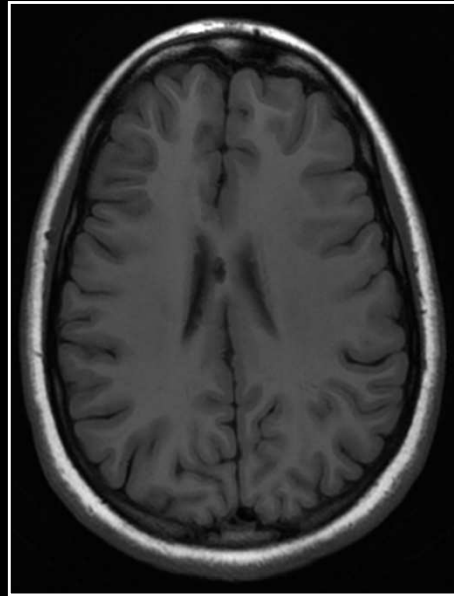
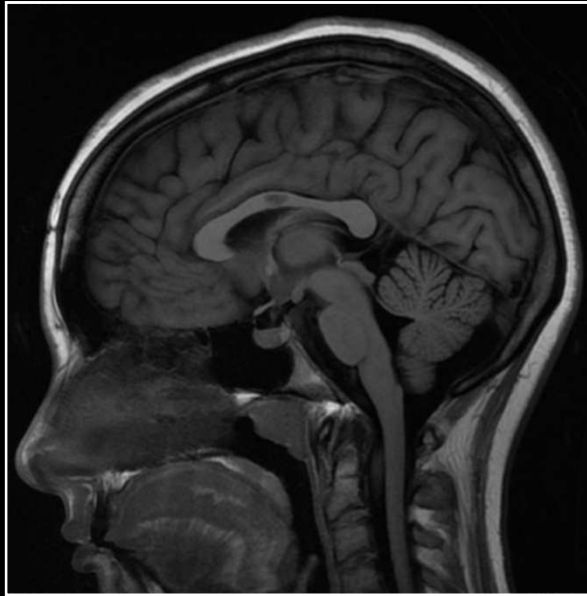
Vasculitis infecciosa (streptococcus pneumoniae)



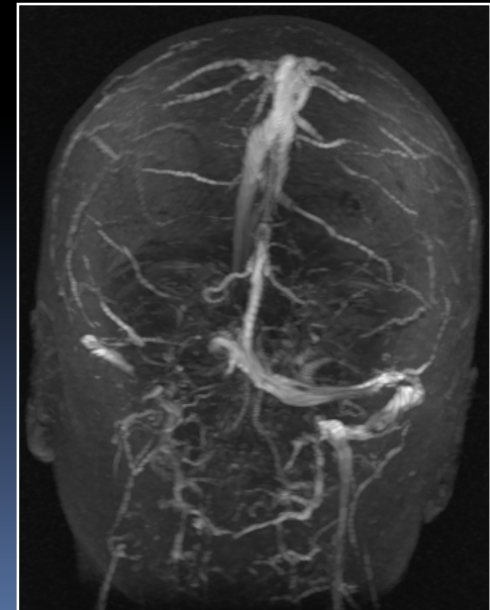
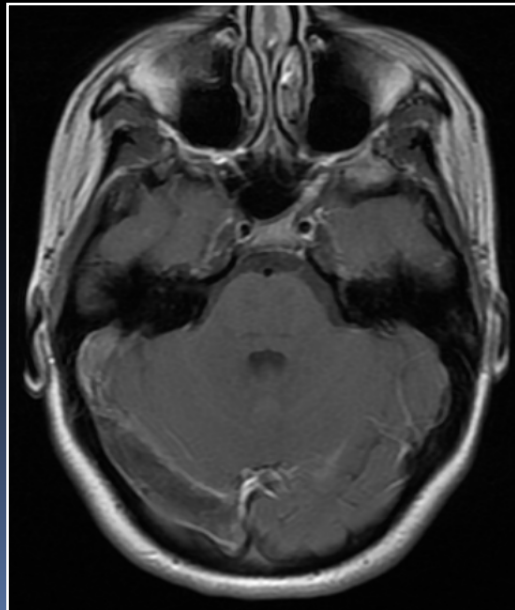
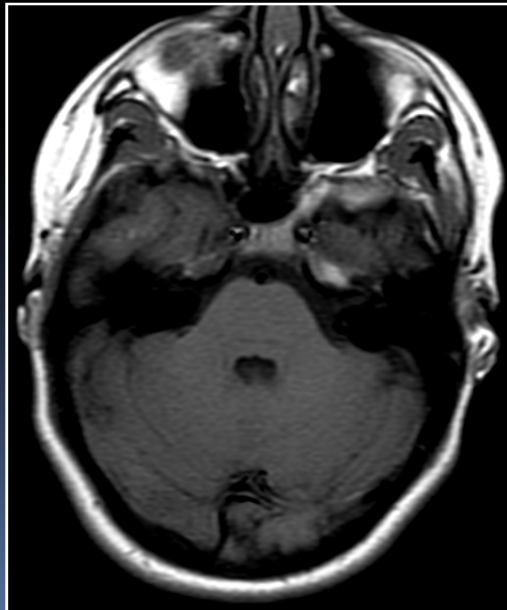
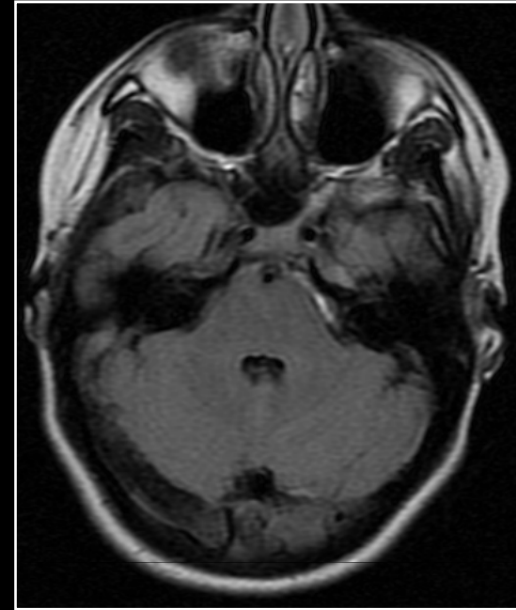
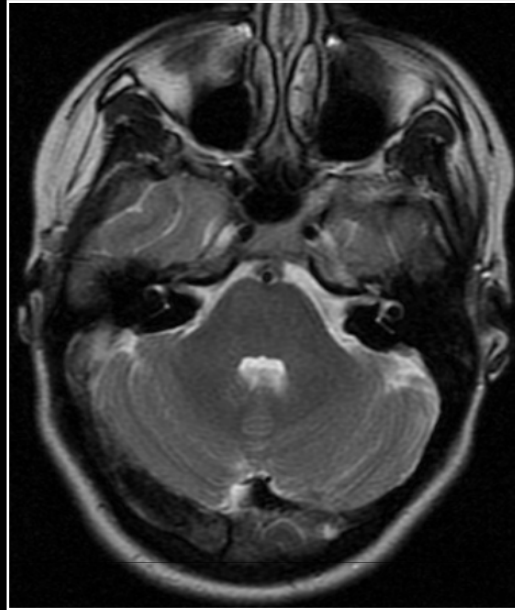
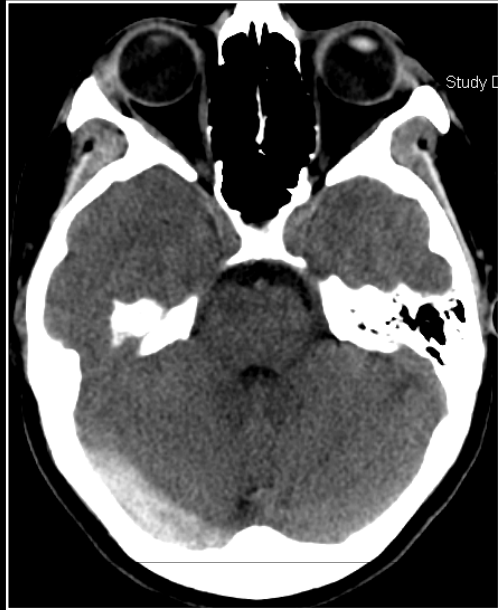
Vasculitis infecciosa (virus varicela zoster)



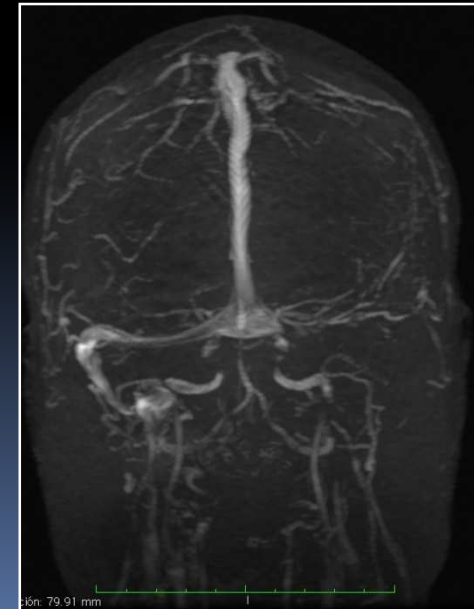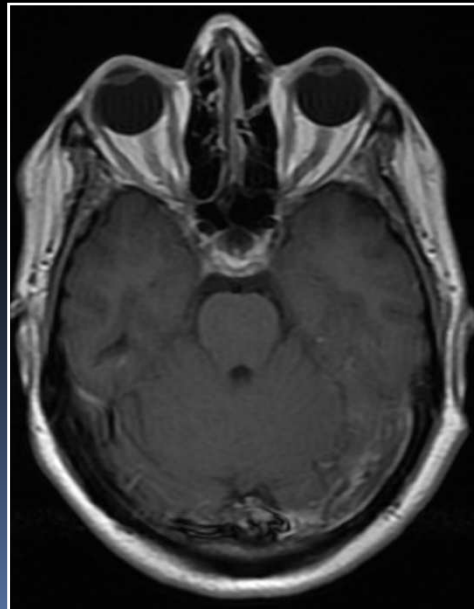
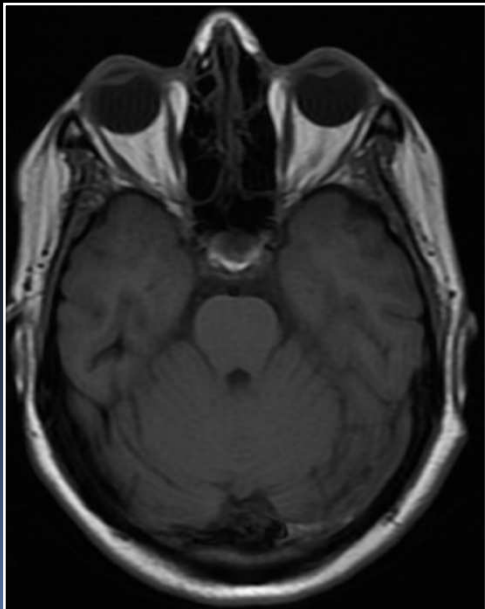
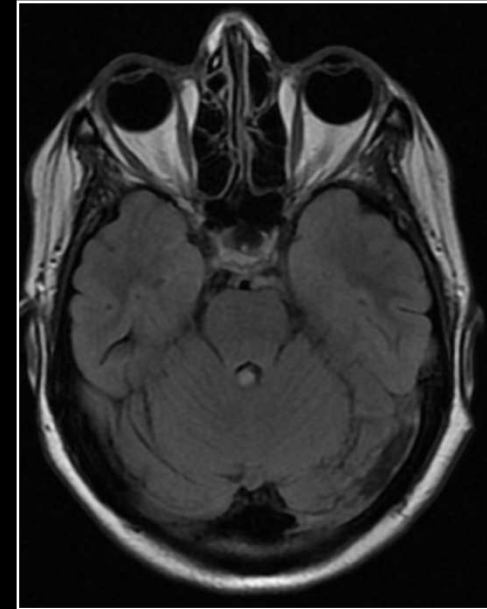
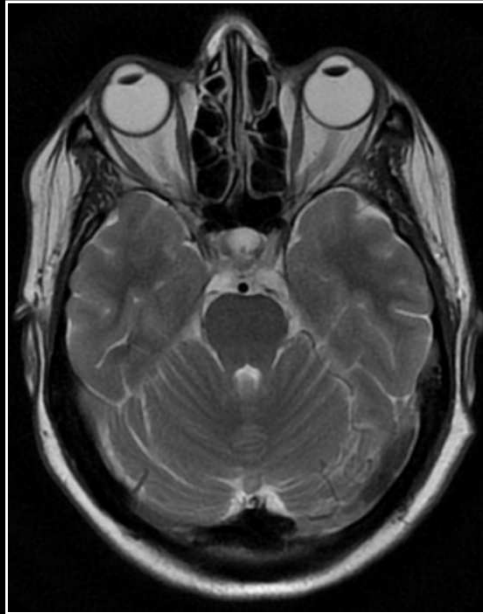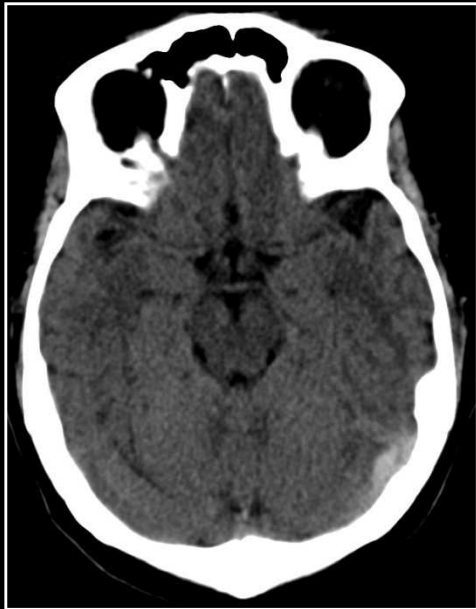Síndrome antifosfolípídico



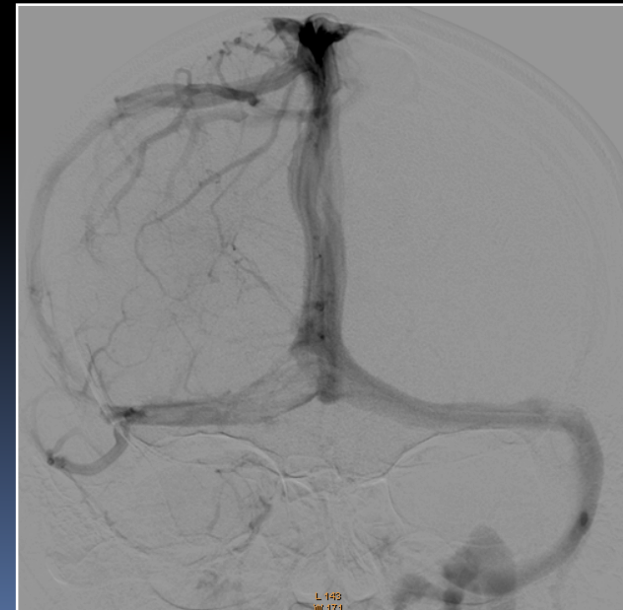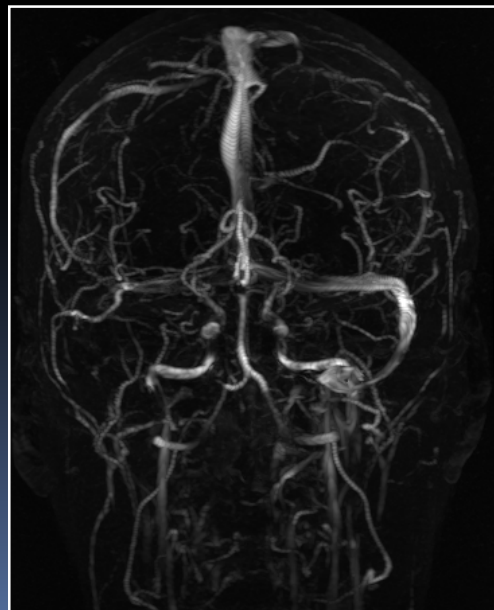
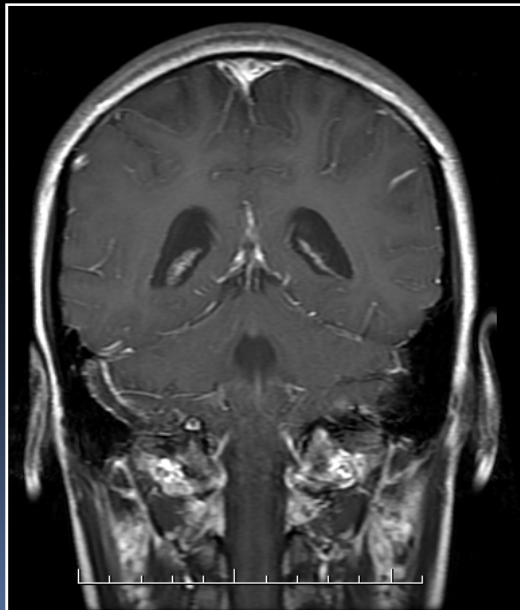
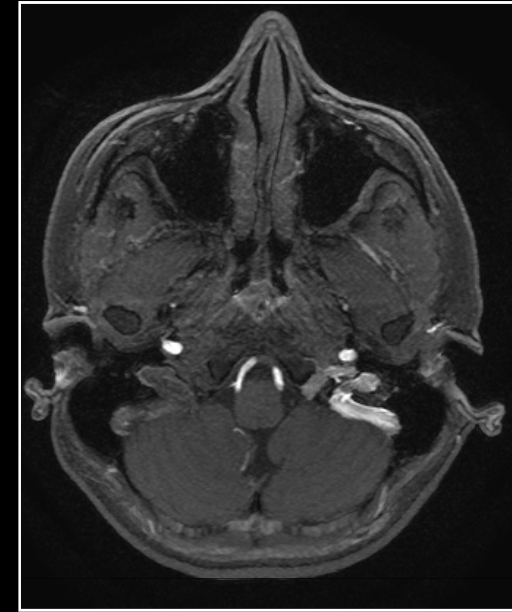
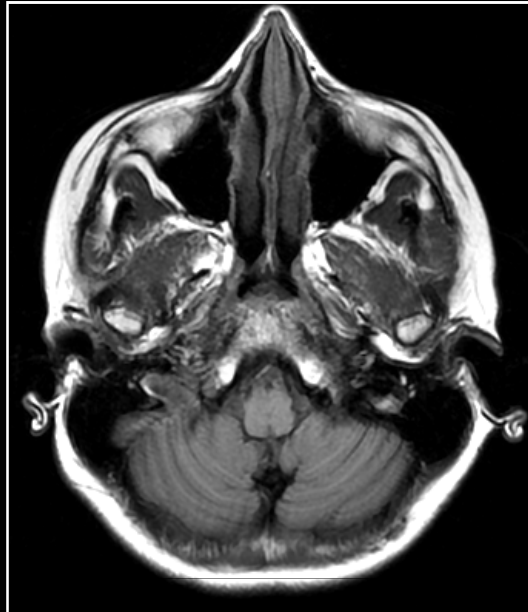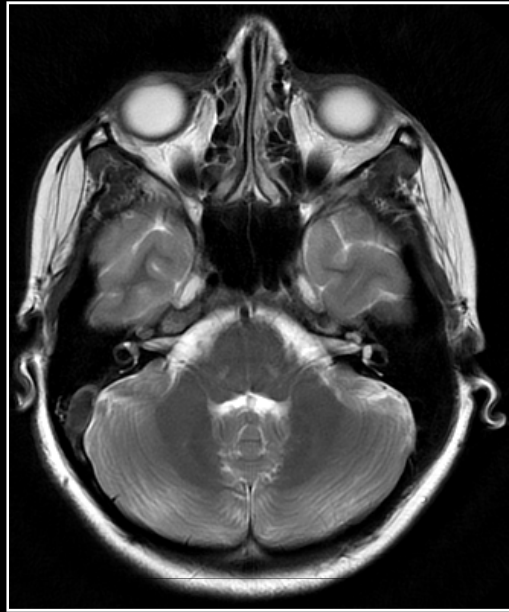
Trombosis venosa cerebral



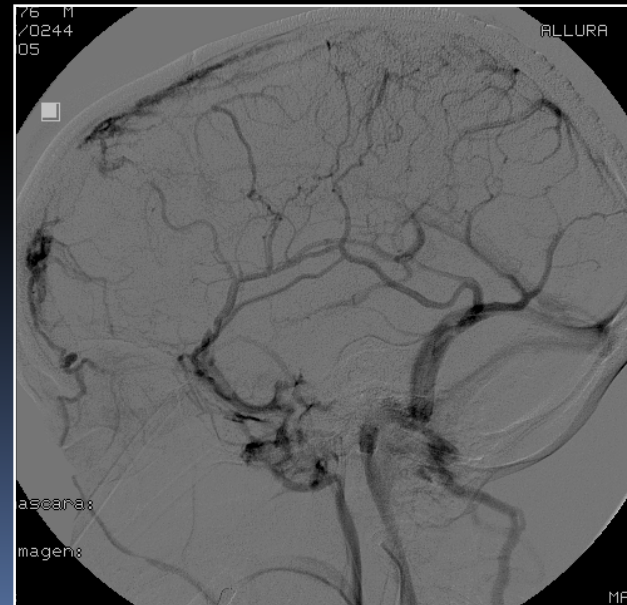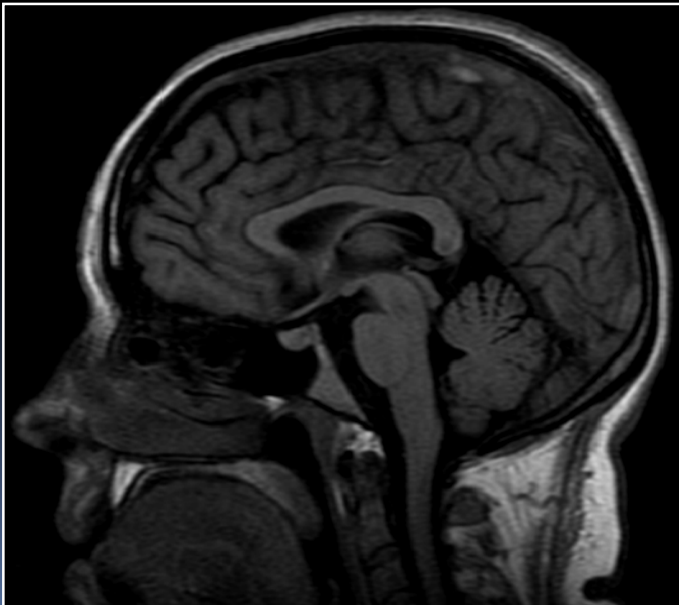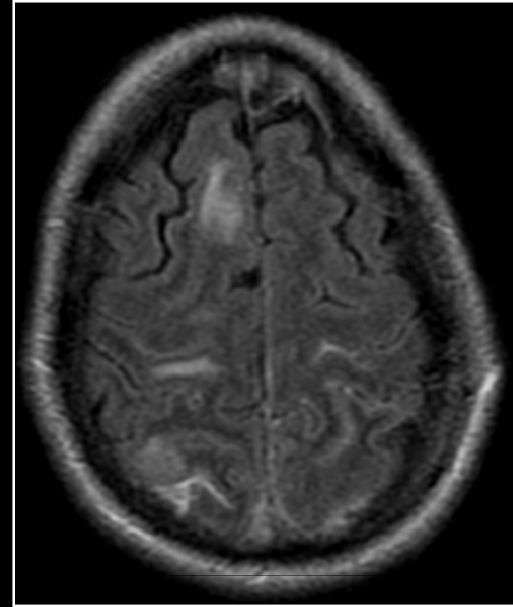
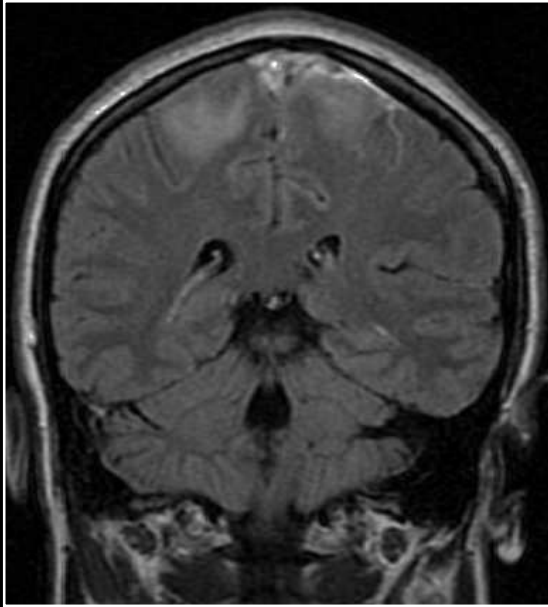
Trombosis venosa cerebral



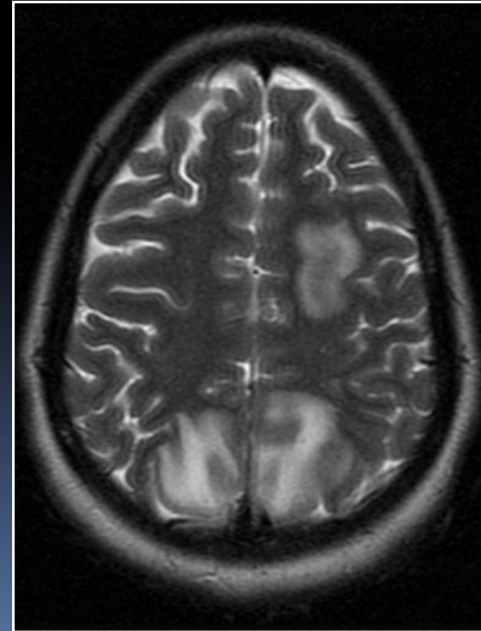
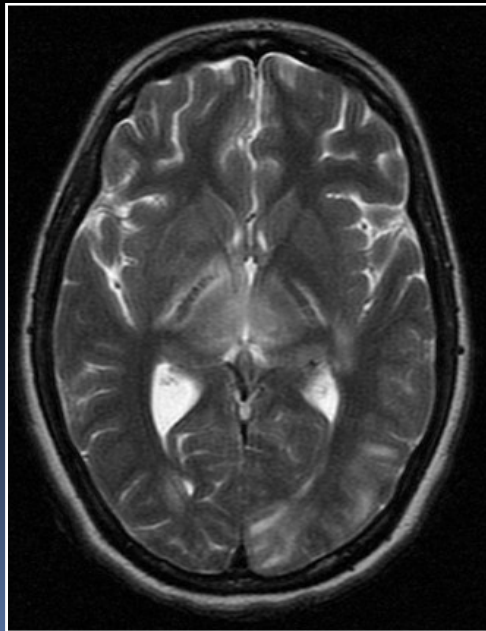
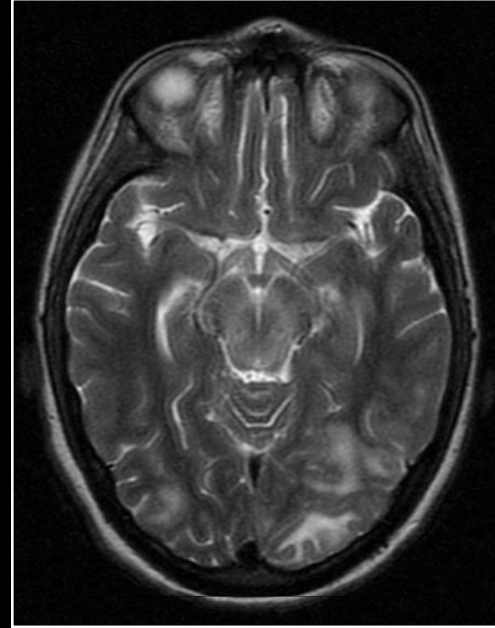
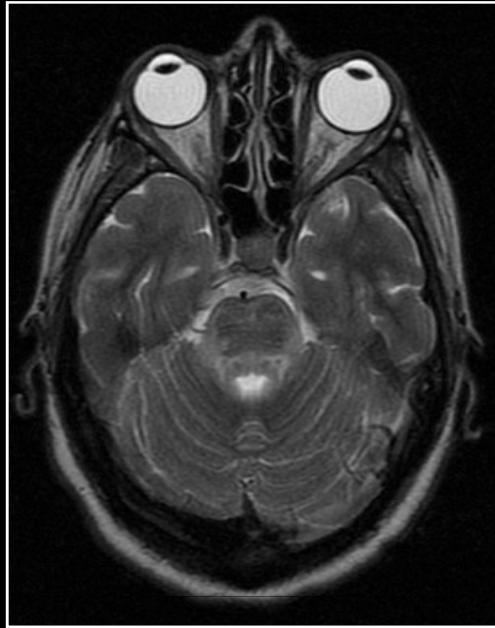Trombosis venosa cerebral



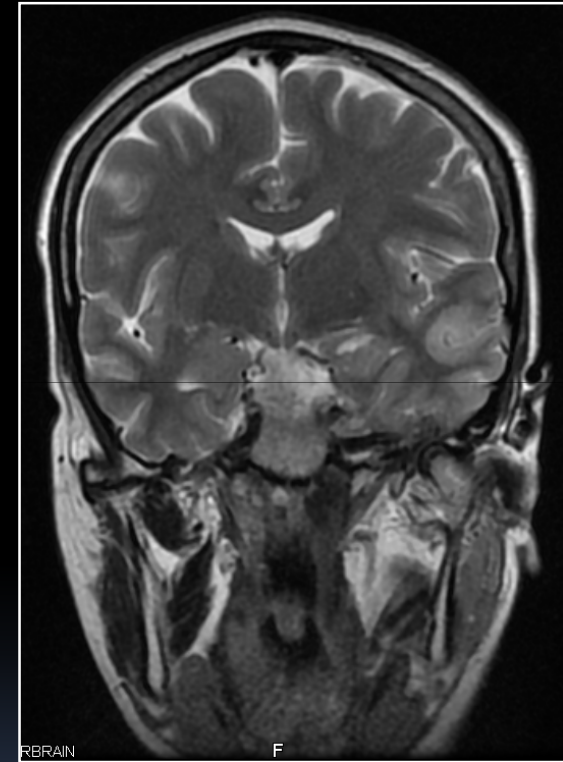
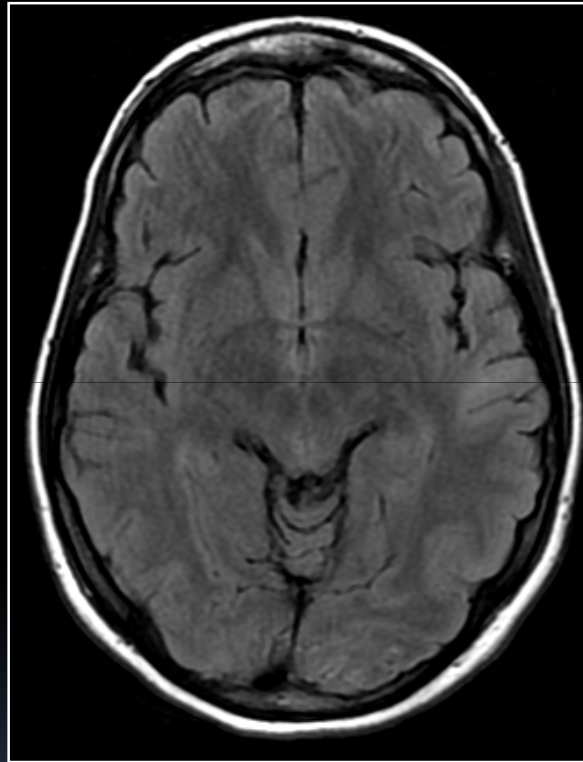
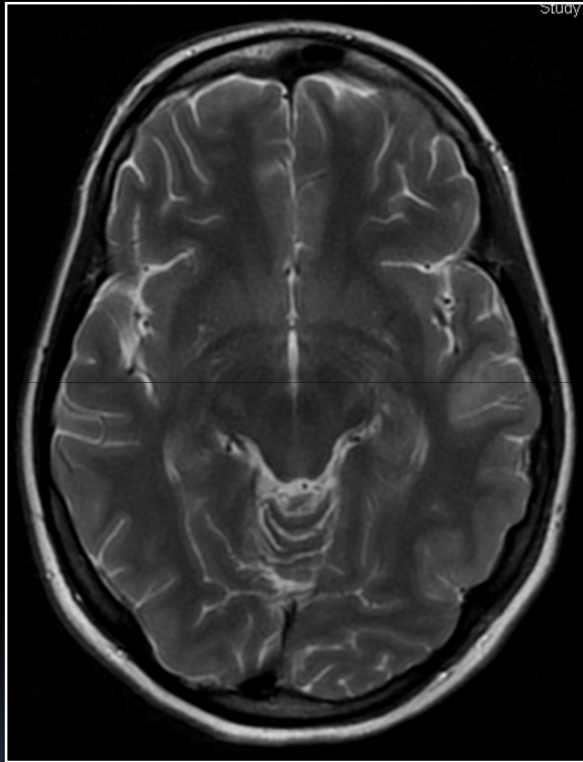
Trombosis venosa cerebral



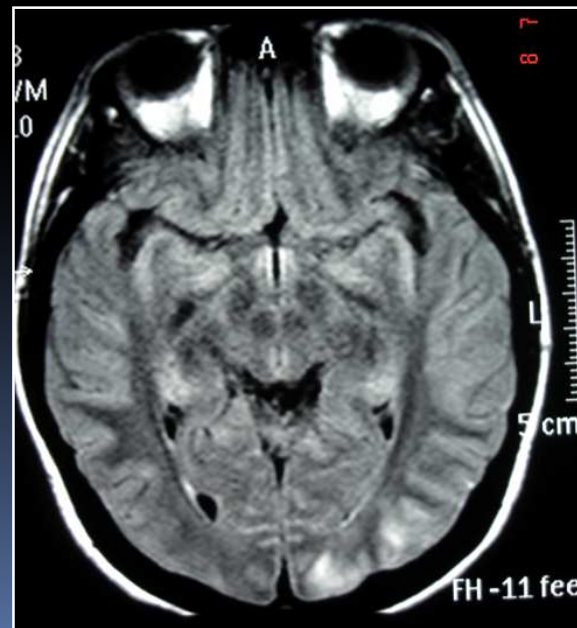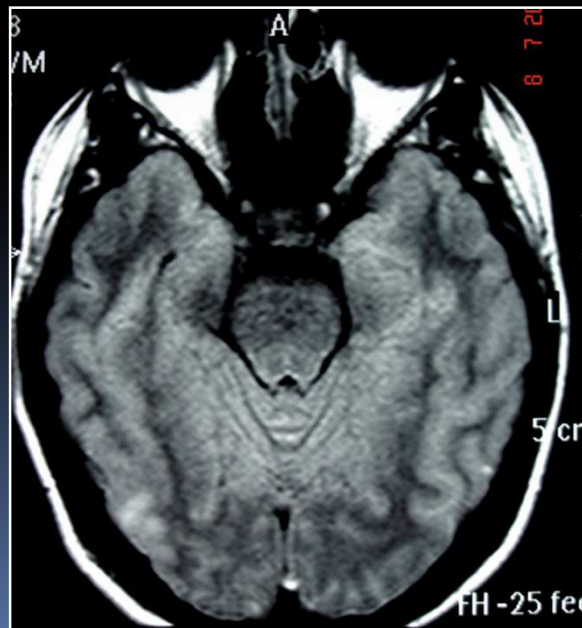
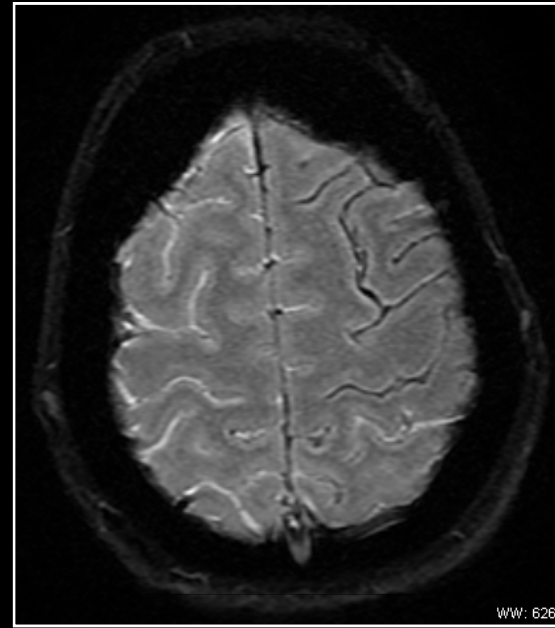
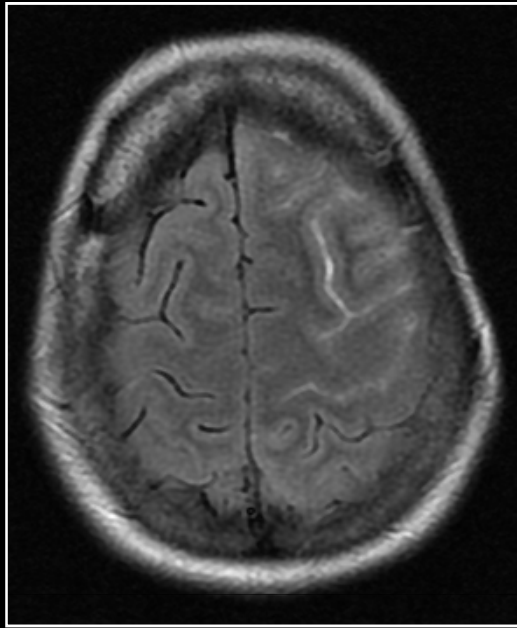
Eclampsia, leucoencefalopatía posterior reversible



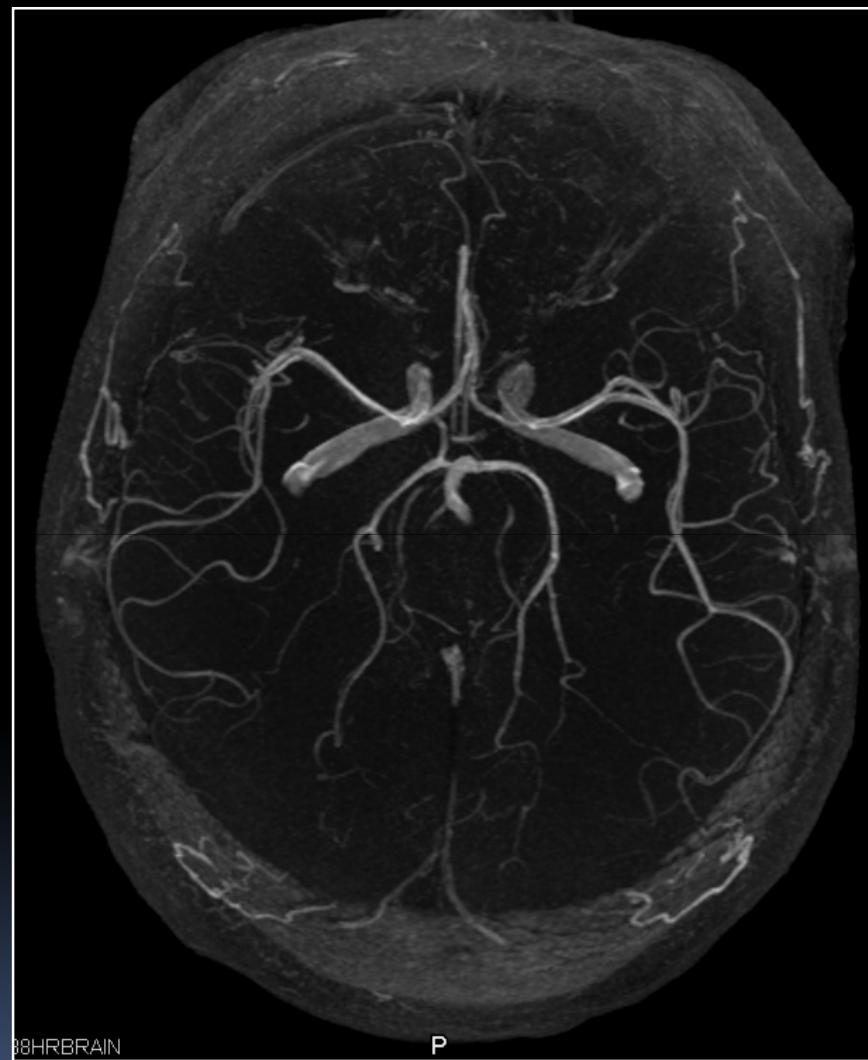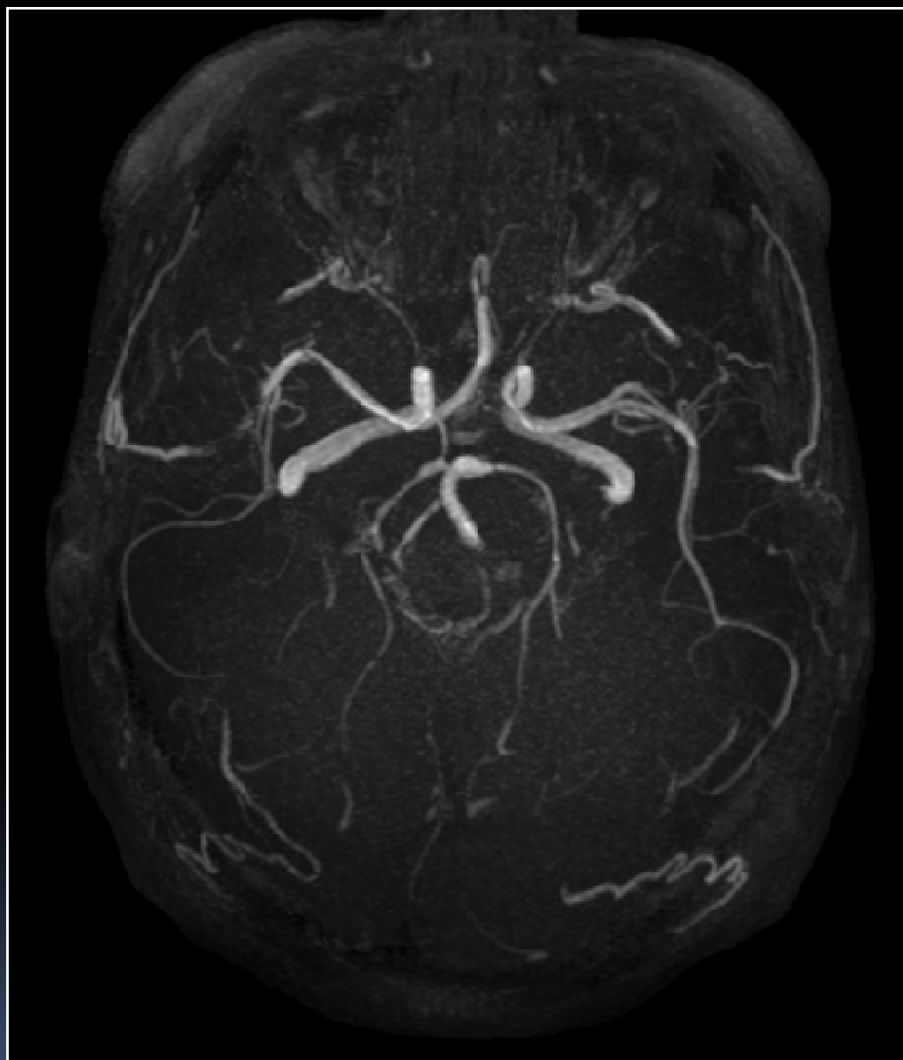Eclampsia, leucoencefalopatía posterior reversible



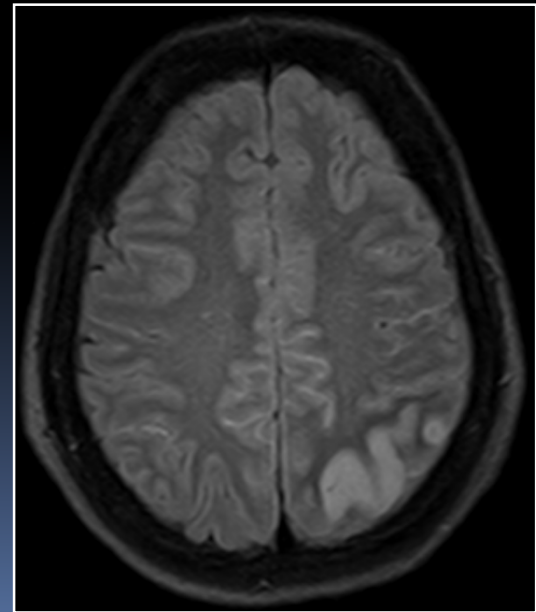
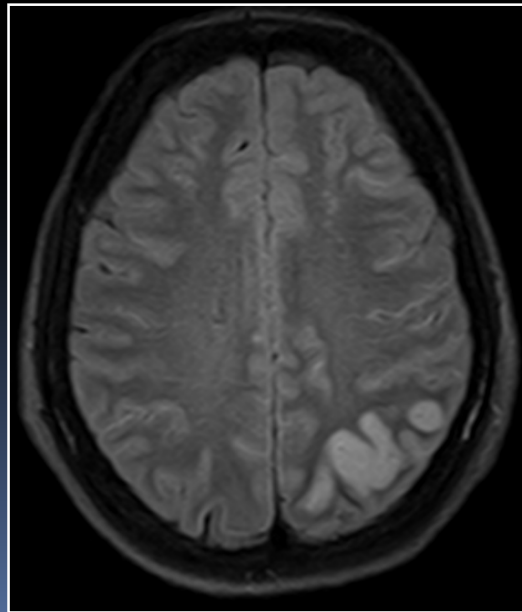
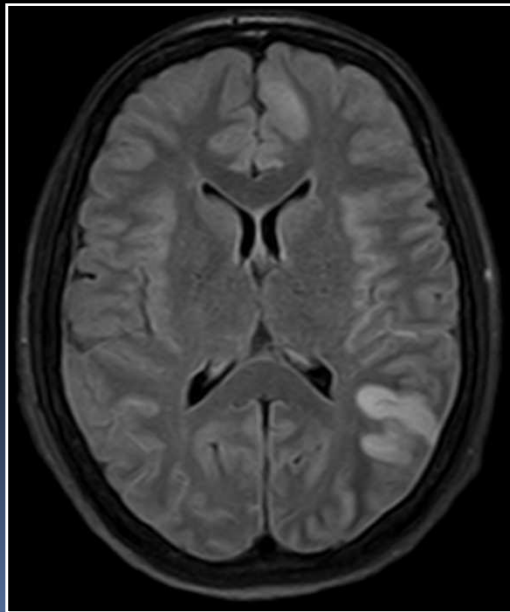
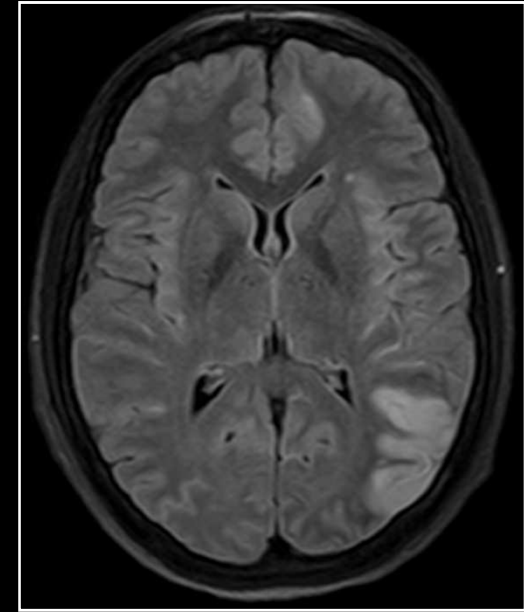
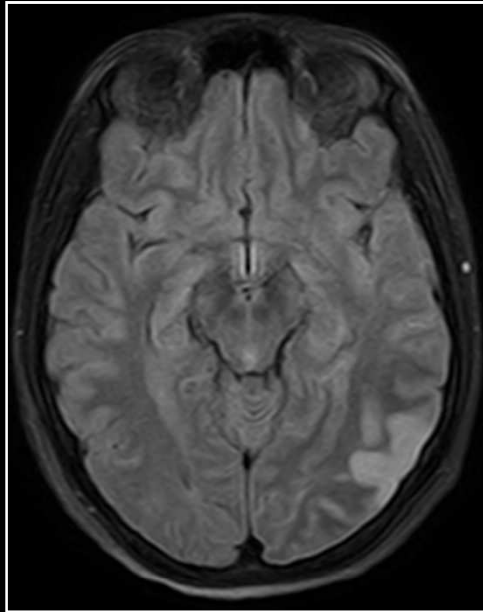
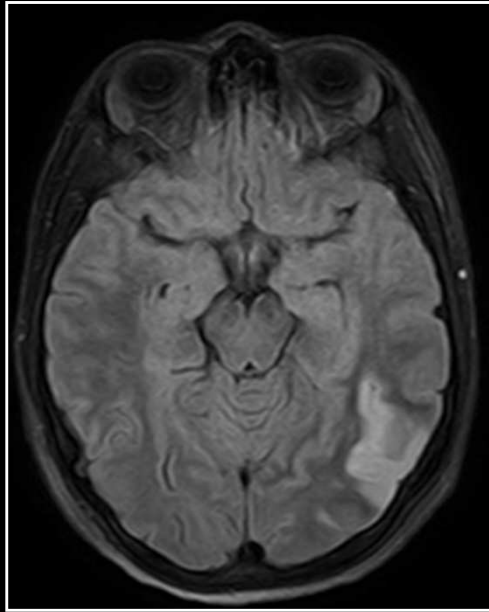
Eclampsia, leucoencefalopatía posterior reversible, HSA cortical



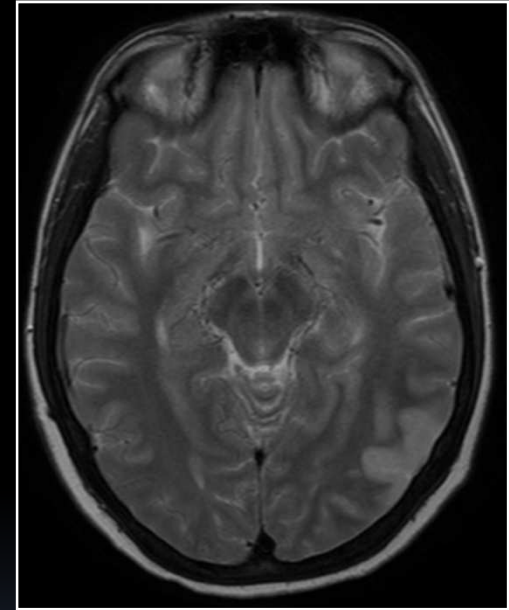
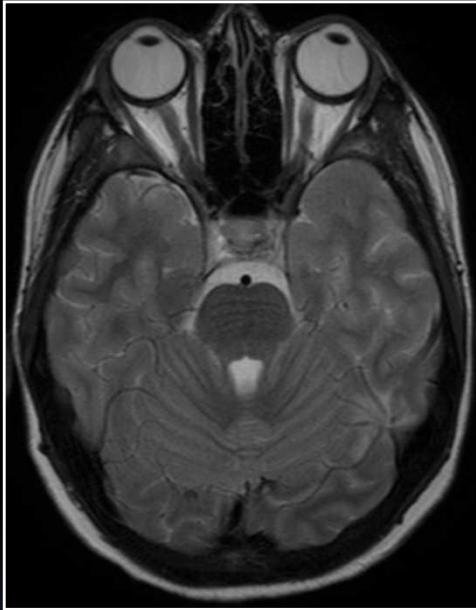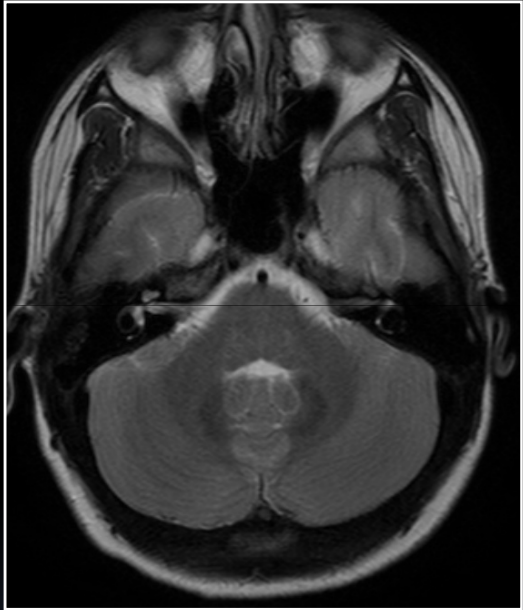Eclampsia, vasoespasm arterial cerebral



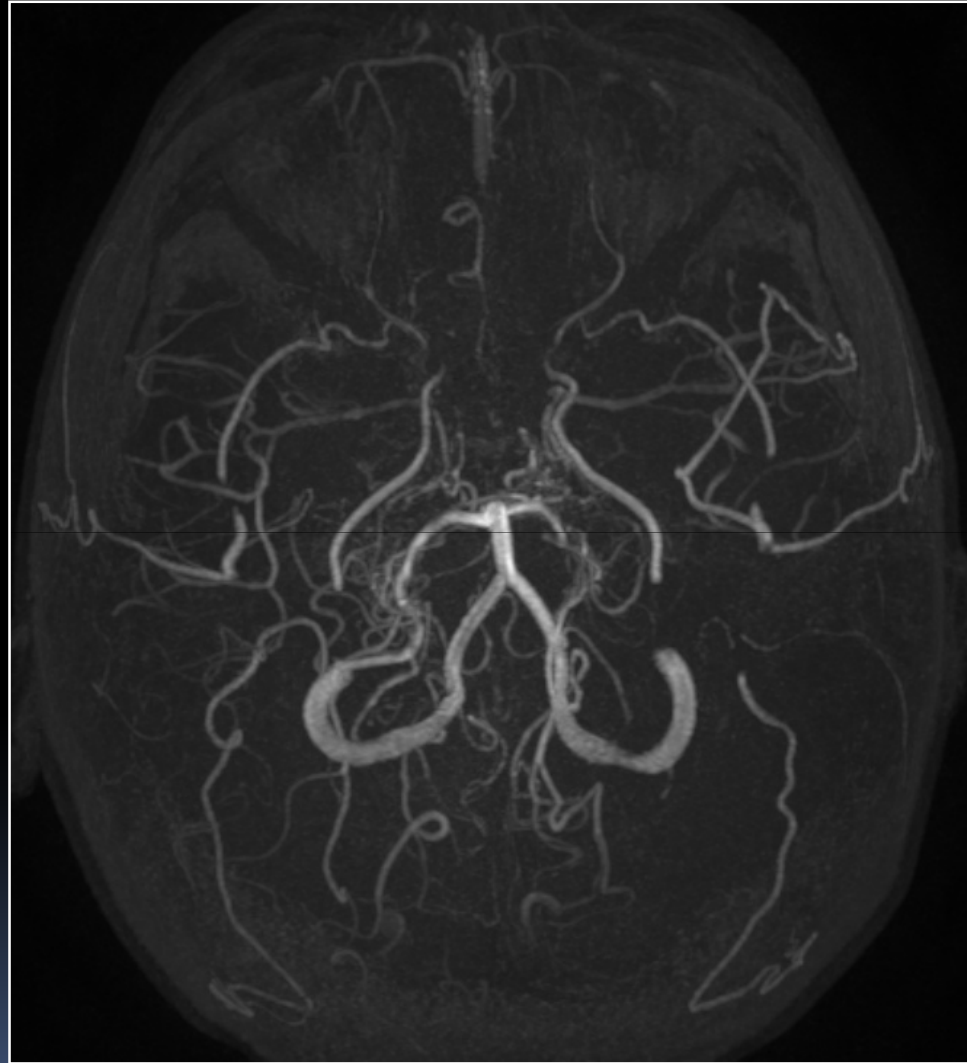Síndrome de moyamoya



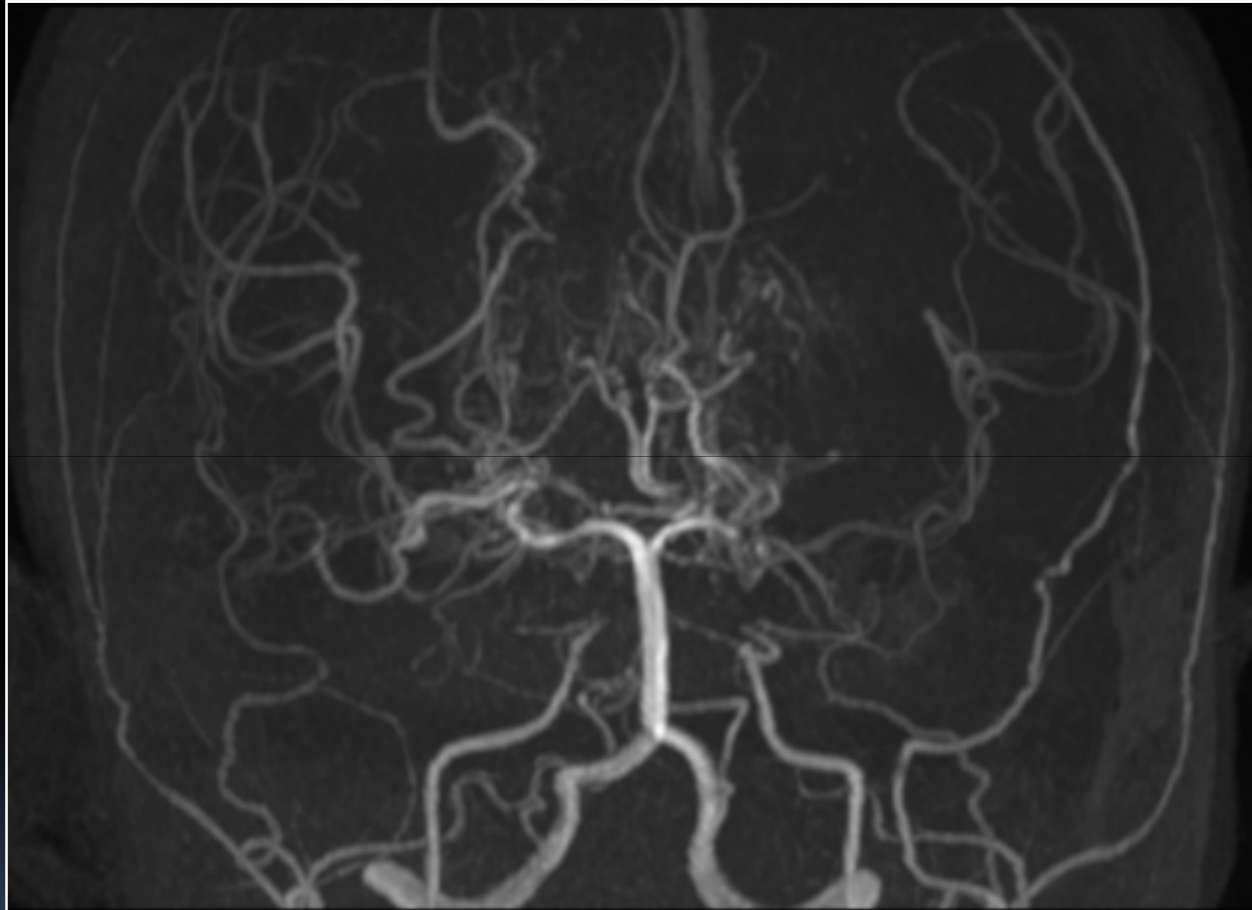
Síndrome de moyamoya



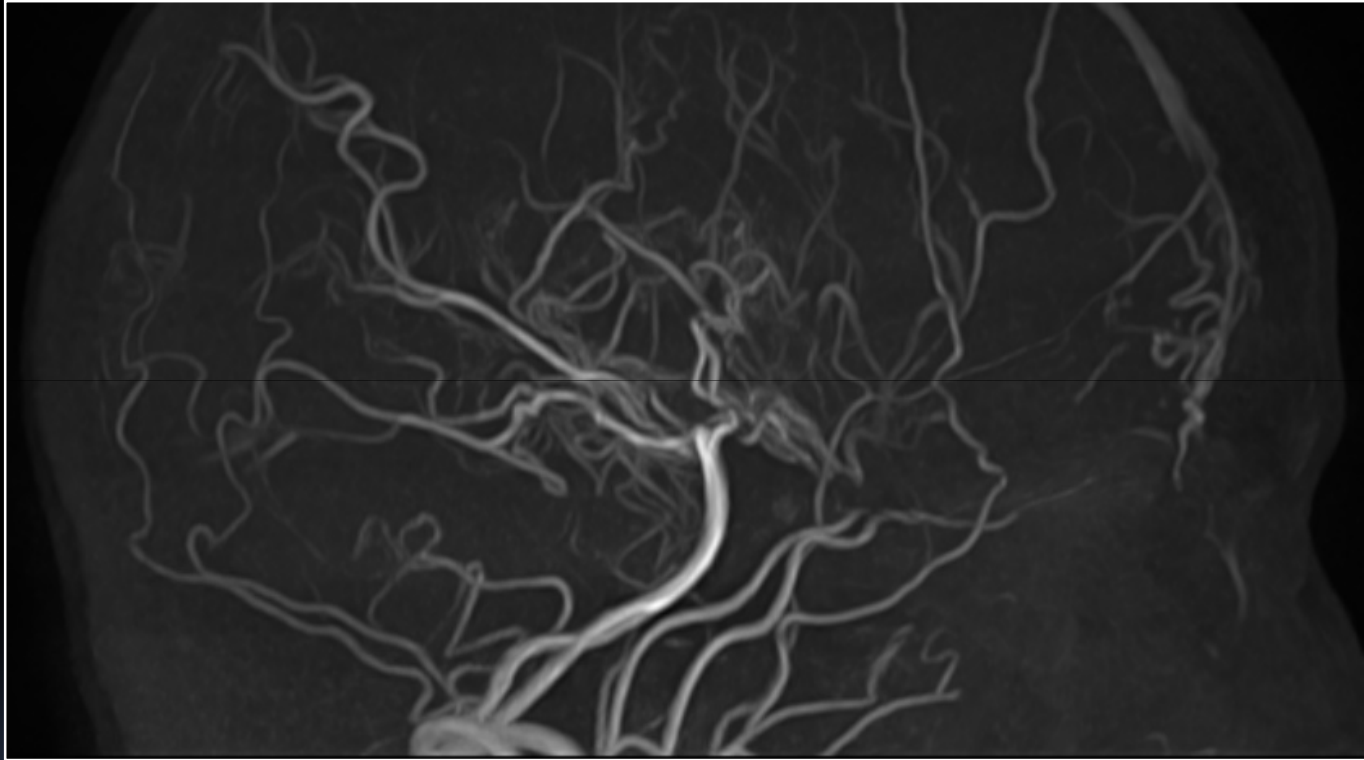
Síndrome de moyamoya



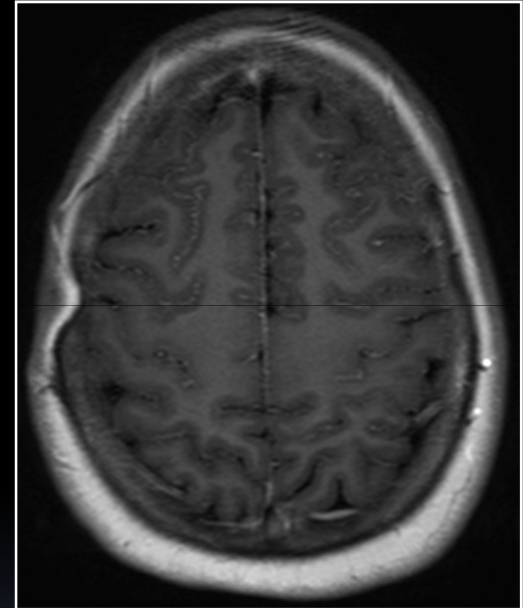
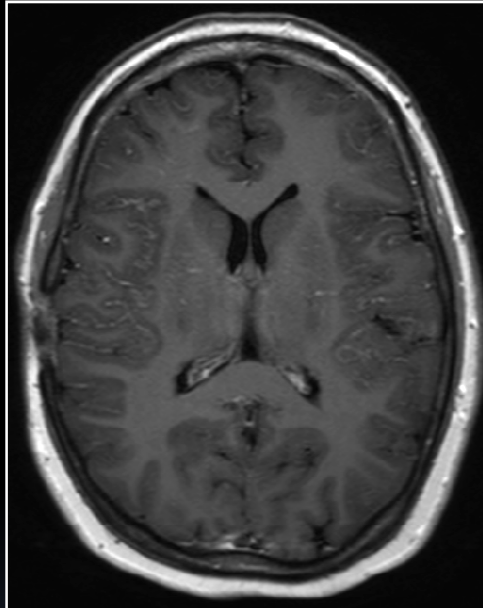
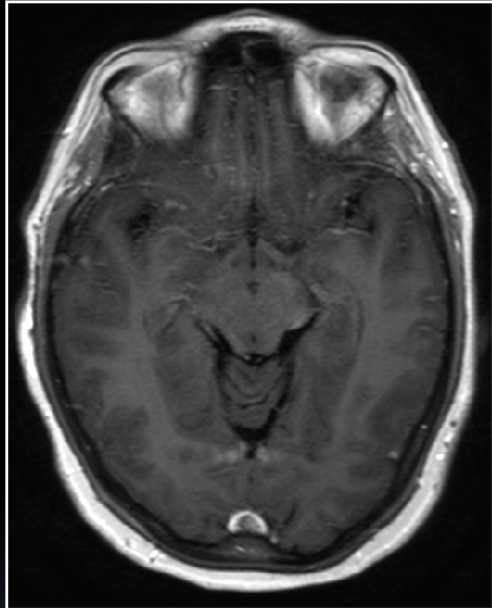
Síndrome de moyamoya



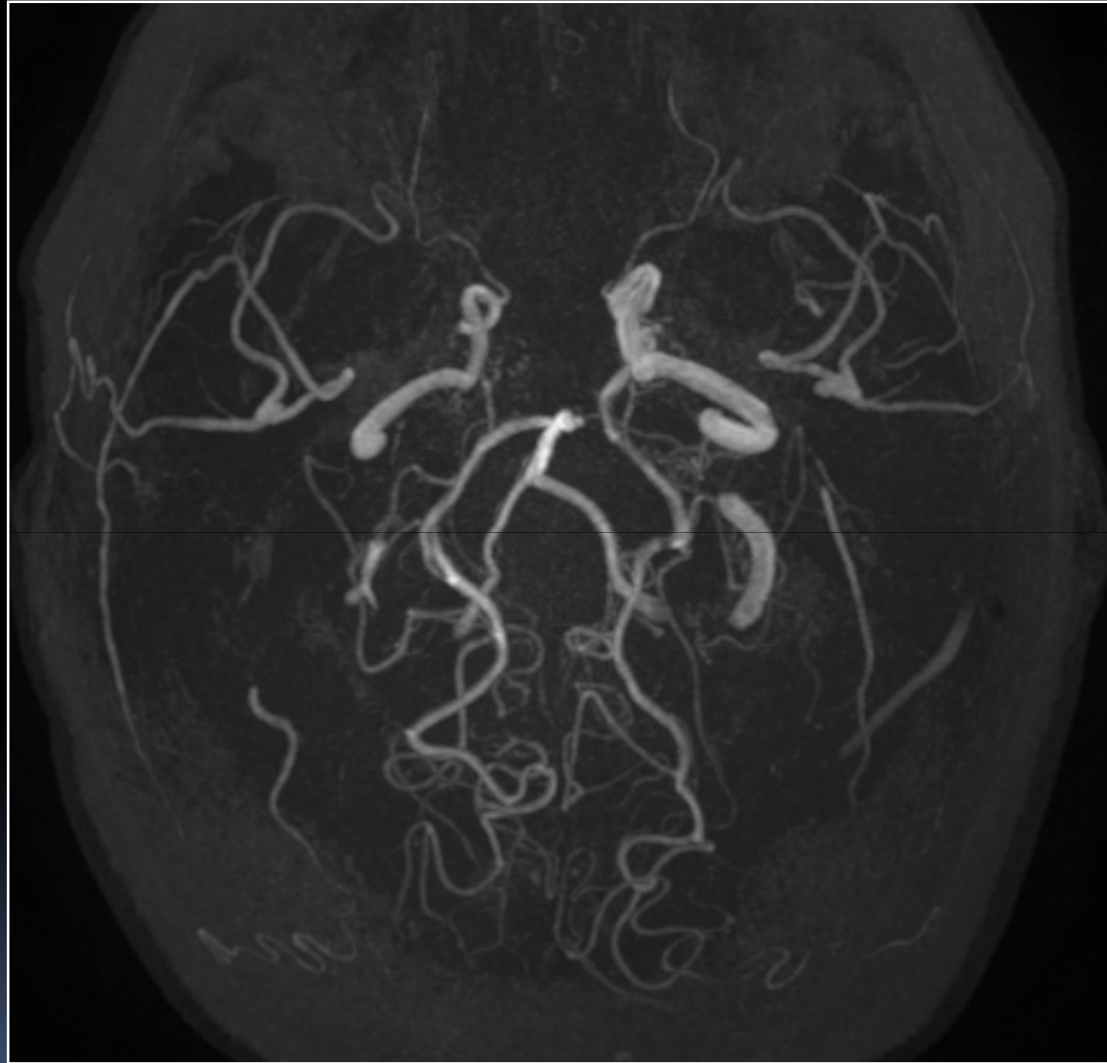
Síndrome de moyamoya



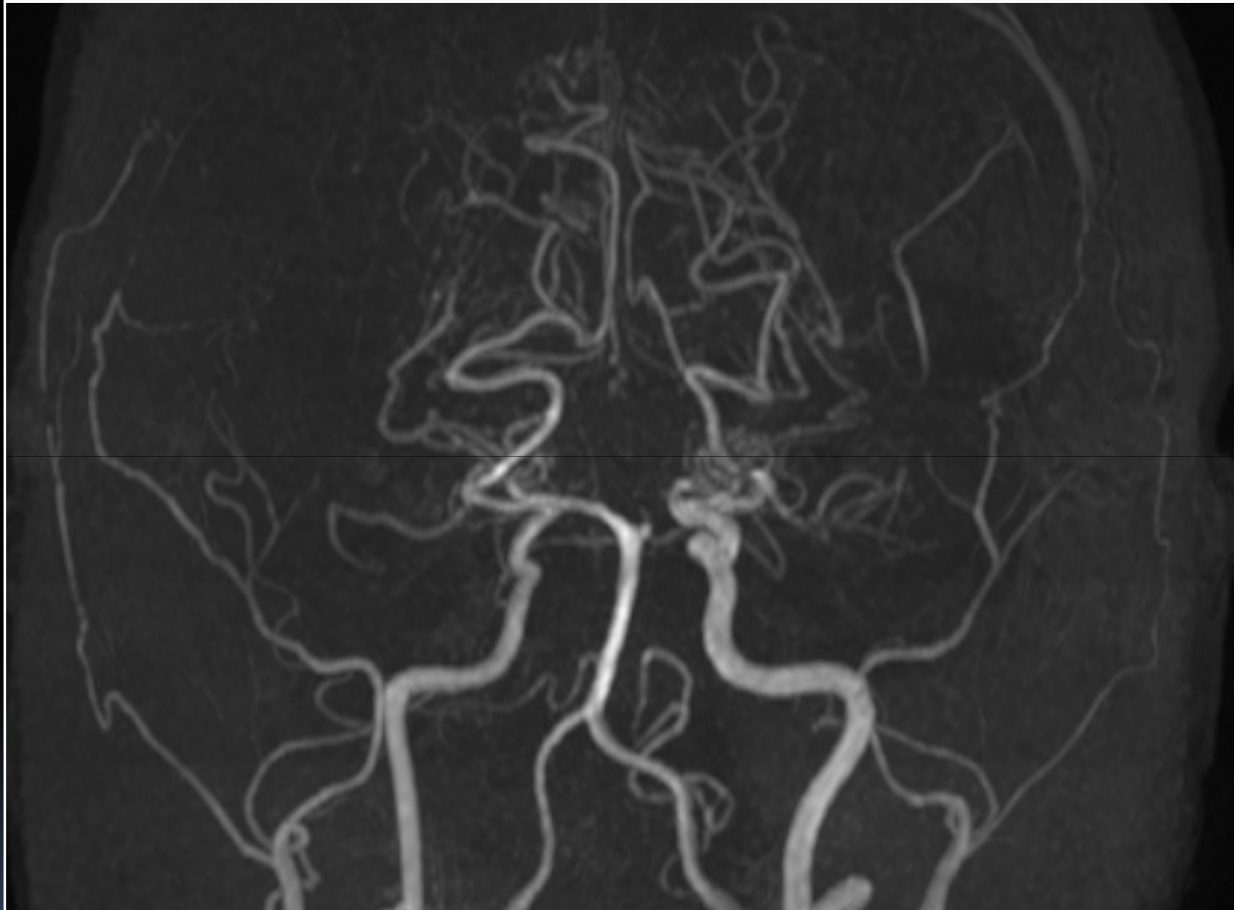
Síndrome de moyamoya



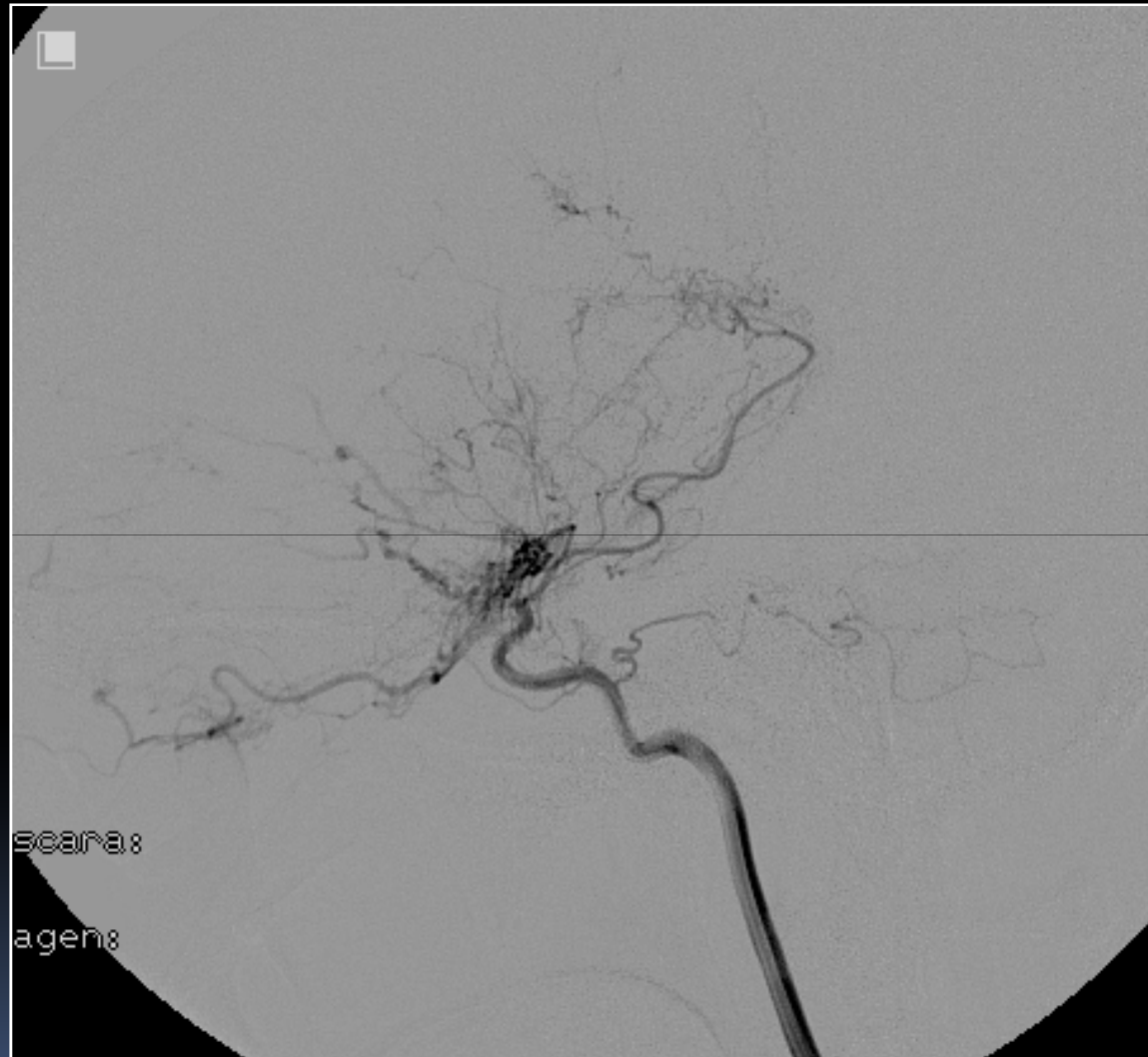Síndrome de moyamoya



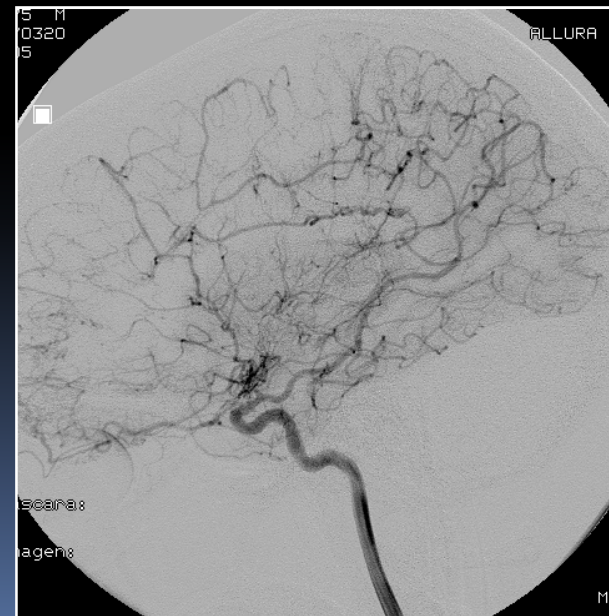
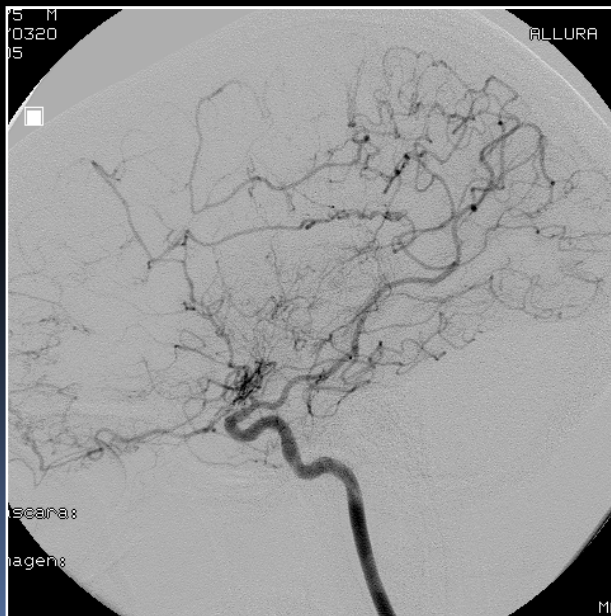
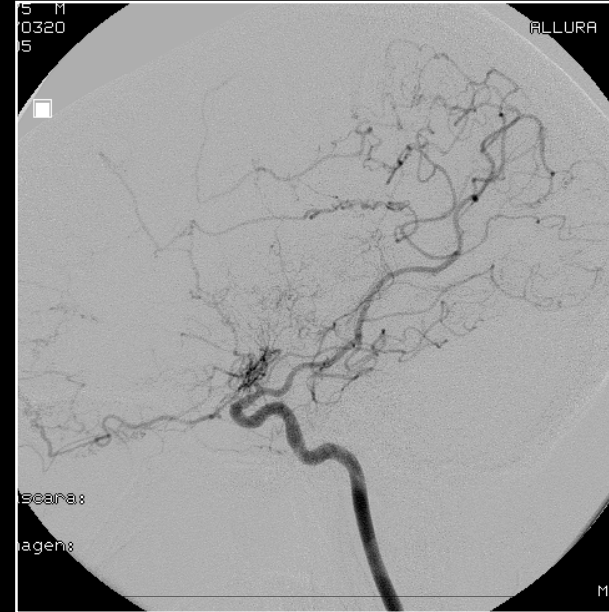
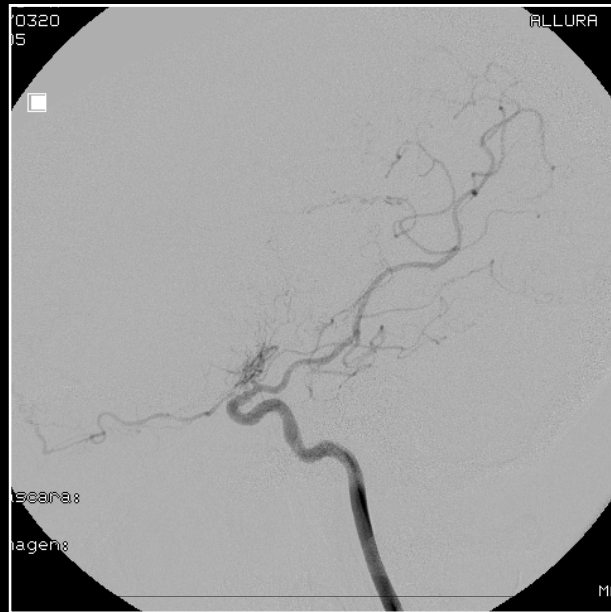
Síndrome de moyamoya



Síndrome de moyamoya



Síndrome de moyamoya



Muchas gracias